

# AMSER Case of the Month: July 2018

19yo F with RLQ abdominal pain



Cecilia Davis-Hayes, MS4

Columbia University Vagelos College of Physicians & Surgeons



Mentor: Dr. Pallavi Utukuri, CUMC Dept of Radiology



# Patient Presentation

- 19yo F BIBEMS for evaluation of RLQ pain with nausea and vomiting
  - Cramping, constant, 10/10, non-radiating, abrupt onset this morning
- PMHx: Mild intermittent asthma
- GYNHx:
  - No prior Pap; No Hx of STIs; No prior pregnancies, miscarriages, or abortions
  - LMP 06/06/2018
  - Copper IUD placed 06/05/18
- Physical Exam
  - VS: 36.7° C HR 68 BP 124/64 RR 18 SpO2: 100%
  - Abdominal: RLQ TTP and + Rovsing's Sign
  - Pelvic: No blood in vaginal vault, IUD strings visible, no cervical motion or adnexal tenderness/ Bimanual: Palpable mass R adnexa

# Pertinent Labs

- WBC: 13.8, Hgb: 11.9
- BUN: 14, Cr: 0.59
- Lipase: 17
- B-HCG: negative
- Urinalysis: normal

What Imaging Should We Order?

# ACR Appropriateness Criteria: RLQ Pain

## American College of Radiology ACR Appropriateness Criteria®

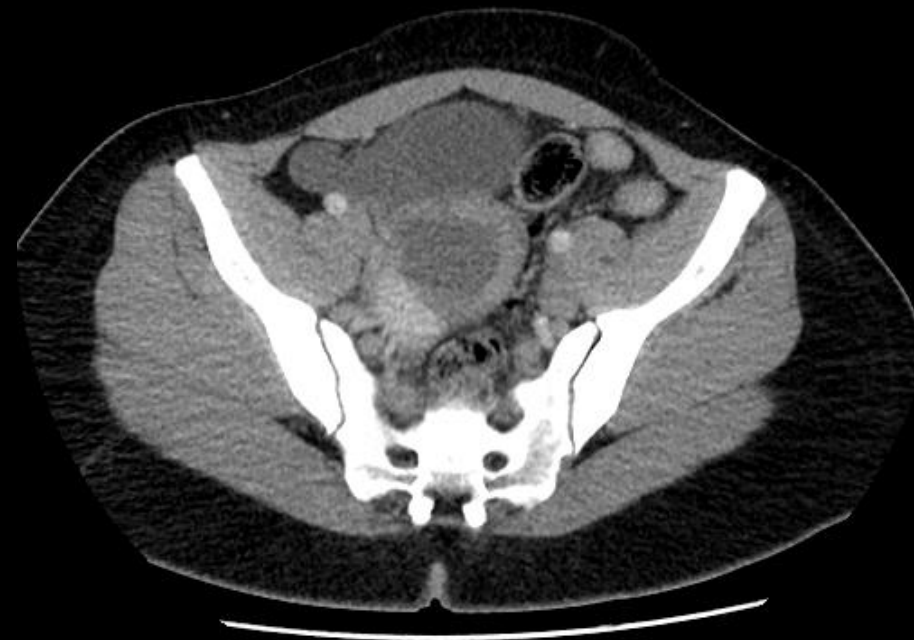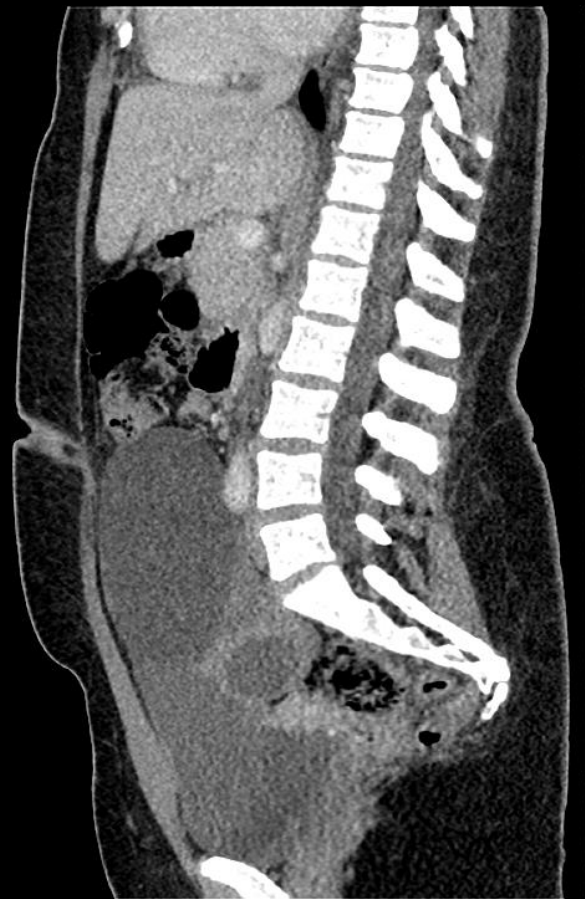**Clinical Condition:** Right Lower Quadrant Pain—Suspected Appendicitis

**Variant 1:** Fever, leukocytosis, and classic clinical presentation for appendicitis in adults.

Radiologic Procedure	Rating	Comments	RRL*
CT abdomen and pelvis with IV contrast	8	Oral or rectal contrast may not be needed depending on institutional preference.	☼☼☼☼
CT abdomen and pelvis without IV contrast	7	Use of oral or rectal contrast depends on institutional preference.	☼☼☼☼
US abdomen	6	Perform this procedure with graded compression.	0
US pelvis	5	This procedure is appropriate in women with pelvic pain.	0
MRI abdomen and pelvis without and with IV contrast	5		0
X-ray abdomen	4	This procedure may be useful when there is concern for perforation and free air.	☼☼
CT abdomen and pelvis without and with IV contrast	4	Oral or rectal contrast may not be needed in this procedure depending on institutional preference.	☼☼☼☼
MRI abdomen and pelvis without IV contrast	4		0
X-ray contrast enema	2		☼☼☼
Tc-99m WBC scan abdomen and pelvis	2		☼☼☼☼
<b>Rating Scale:</b> 1,2,3 Usually not appropriate; 4,5,6 May be appropriate; 7,8,9 Usually appropriate			<b>*Relative Radiation Level</b>

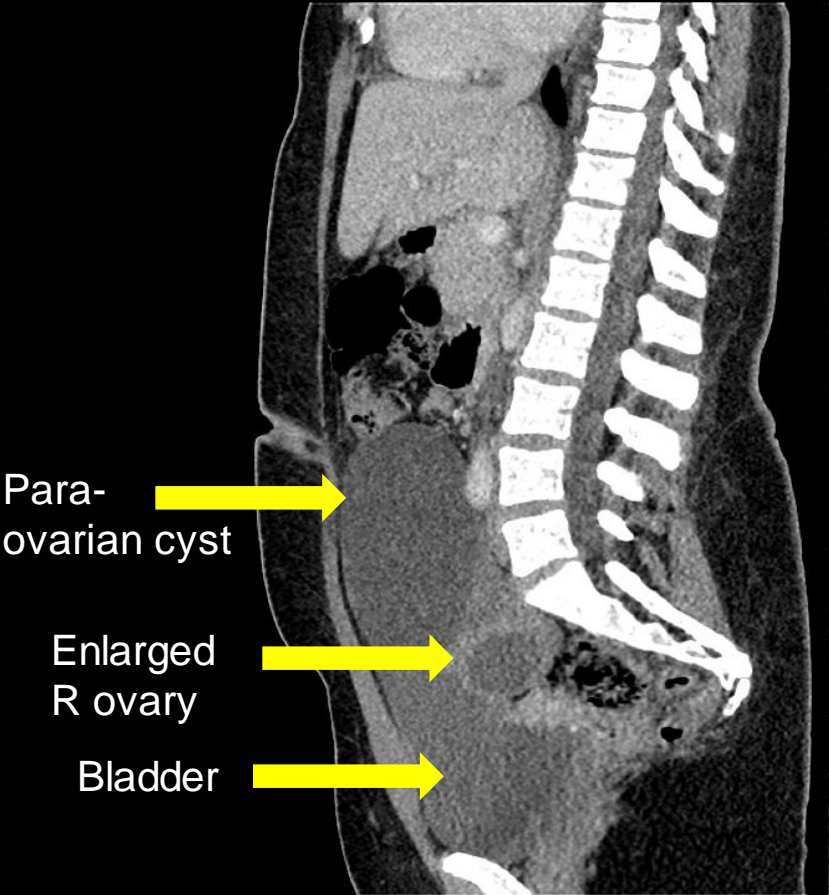
This imaging modality was ordered by the ED physician

# Findings (unlabeled)

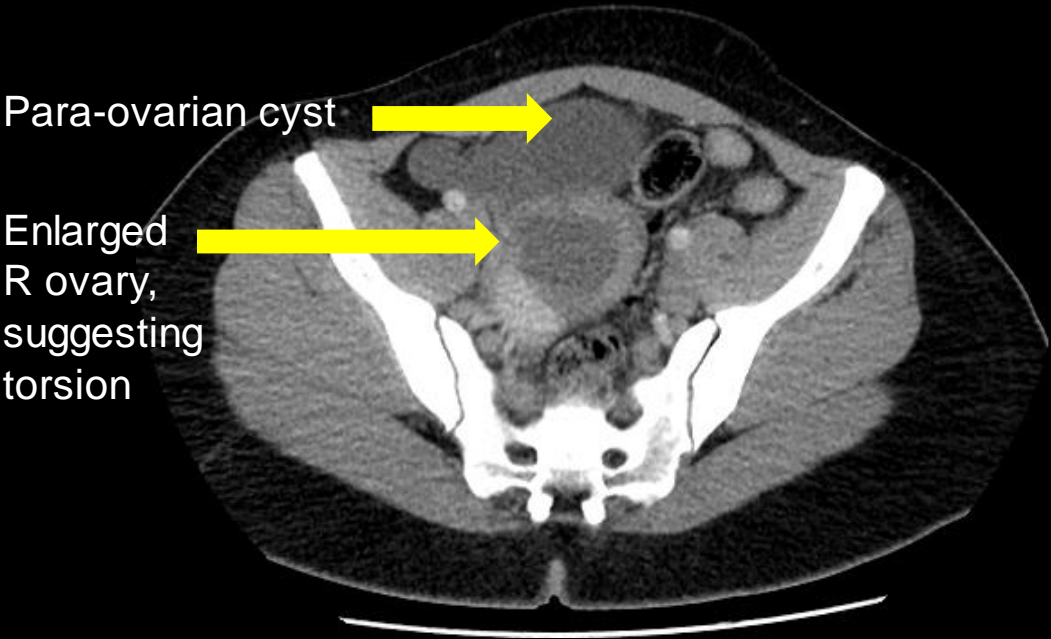


# Findings (labeled)

Sagittal



Axial



What Additional Imaging Should We Order? **AMSER**

# ACR Appropriateness Criteria: Adnexal Mass

## American College of Radiology ACR Appropriateness Criteria®

**Clinical Condition:** Clinically Suspected Adnexal Mass

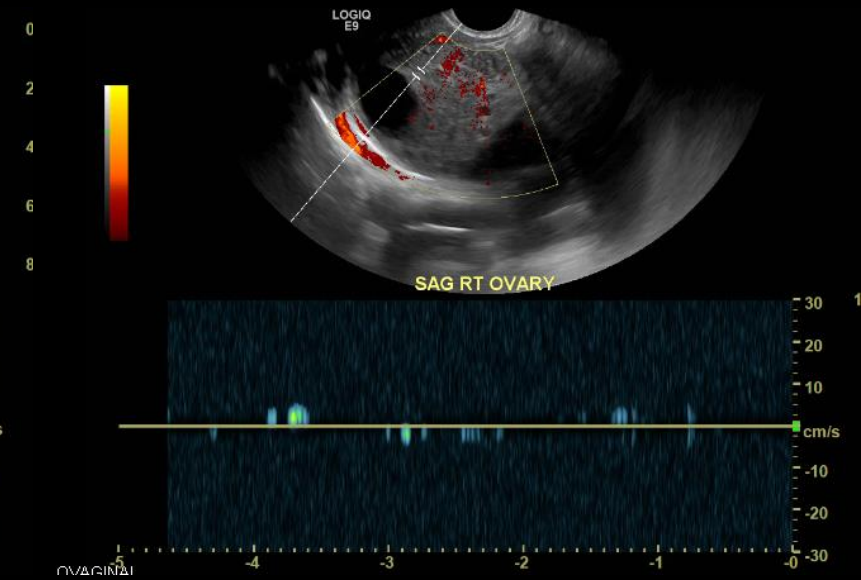
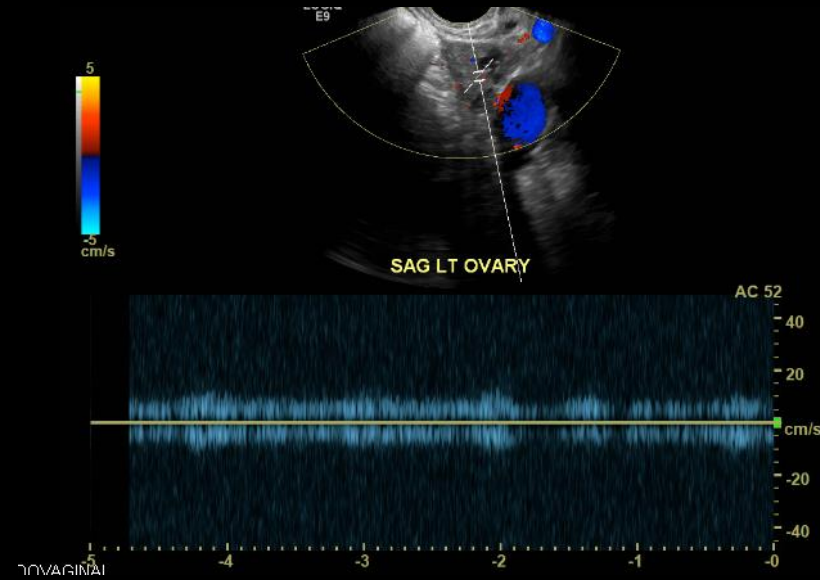
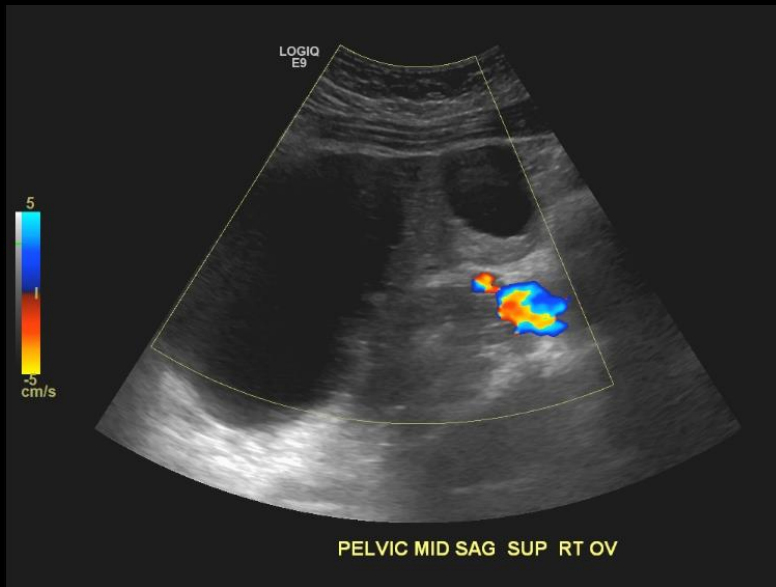
**Variant 1:** Reproductive age female (not pregnant). Initial evaluation.

Radiologic Procedure	Rating	Comments	RRL*
US pelvis transvaginal	9	All three tests (TVS, TAS, and Doppler) may be performed depending on the clinical circumstances.	0
US duplex Doppler pelvis	9	All three tests (TVS, TAS, and Doppler) may be performed depending on the clinical circumstances. Color or power US is recommended, less so spectral Doppler.	0
US pelvis transabdominal	8	All three tests (TVS, TAS, and Doppler) may be performed depending on the clinical circumstances.	0
MRI pelvis without and with IV contrast	6		0
MRI pelvis without IV contrast	5		0
CT pelvis without IV contrast	2		☻☻☻
CT pelvis with IV contrast	2		☻☻☻
CT pelvis without and with IV contrast	2		☻☻☻☻
Image-guided aspiration or biopsy adnexal mass	2		Varies
FDG-PET/CT whole body	1		☻☻☻☻
<b>Rating Scale:</b> 1,2,3 Usually not appropriate; 4,5,6 May be appropriate; 7,8,9 Usually appropriate			<b>*Relative Radiation Level</b>



These imaging modalities were ordered by the ED physician

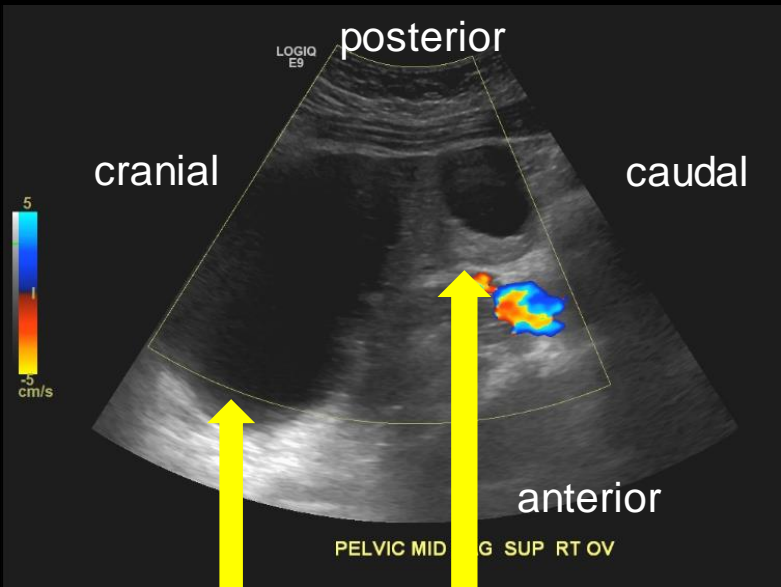
# Findings (unlabeled)





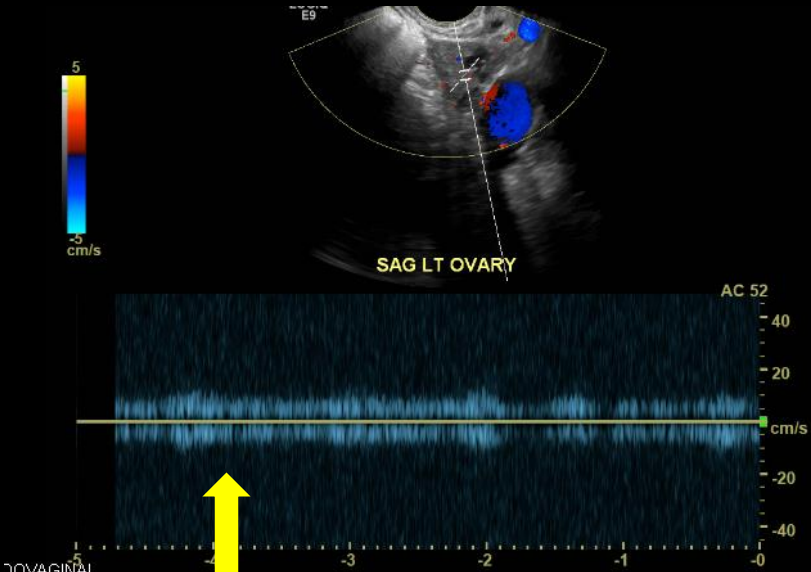
# Findings (labeled)

Transabdominal U/S



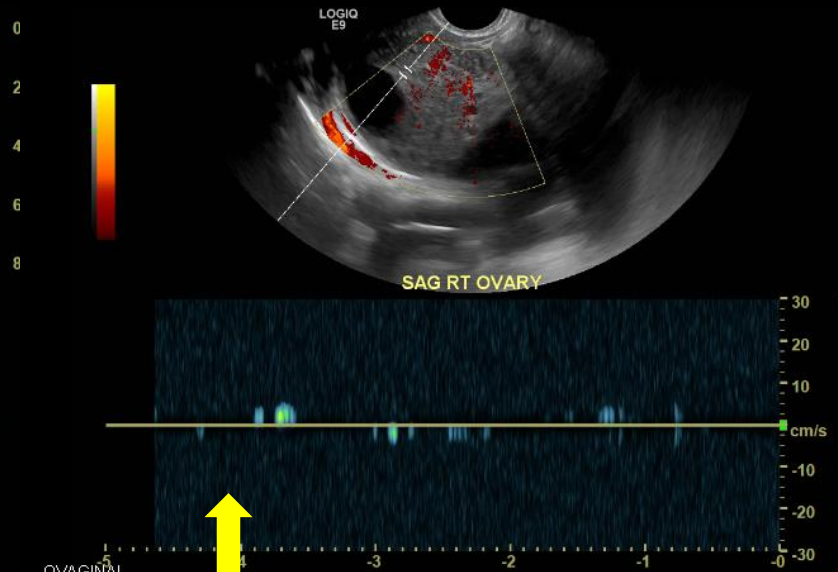
Para-ovarian cyst  
Enlarged R ovary

Transvaginal U/S (Left)



Intact waveform,  
indicating good blood  
flow to L ovary

Transvaginal U/S (Right)



Absent waveform,  
indicating diminished  
blood flow to R ovary

Final Dx:

Right Ovarian Torsion with necrosis

# Ovarian Torsion

- Definition: Rotation of the ovary around the infundibulopelvic and utero-ovarian ligaments → impendence of blood flow
- Risk Factors:
  - Ovarian mass: cyst or neoplasm
  - Reproductive age
- Typical Imaging Findings on U/S
  - Enlarged ovary compared to contralateral- edema and lymph engorgement
  - Ovarian Mass
  - Decreased or absent Doppler flow

- Differential Diagnosis:
  - R/o ectopic pregnancy, appendicitis, and tubo-ovarian abscess
- Surgical Evaluation
  - Confirm Torsion
  - Assess ovarian viability



Detorsion &  
ovarian  
conservation

Salpingo-  
oophrectomy

# References:

Varras M, Tsikini A, Polyzos D, et al. Uterine adnexal torsion: pathologic and gray-scale ultrasonographic findings. Clin Exp Obstet Gynecol 2004; 31:34.

Albayram F, Hamper UM. Ovarian and adnexal torsion: spectrum of sonographic findings with pathologic correlation. J Ultrasound Med 2001; 20:1083.

R. Bhosale, Mostafa Atri, Robert D. Harris, et al. Acute Pelvic Pain in the Reproductive Age Group. Available at: <https://acsearch.acr.org/docs/69503/Narrative/>. American College of Radiology. Accessed 6/27/18.

[https://www.uptodate.com/contents/ovarian-and-fallopian-tube-torsion?search=ovarian%20torsion&source=search\\_result&selectedTitle=1~71&usage\\_type=default&display\\_rank=1#H16](https://www.uptodate.com/contents/ovarian-and-fallopian-tube-torsion?search=ovarian%20torsion&source=search_result&selectedTitle=1~71&usage_type=default&display_rank=1#H16)