

AMSER Rad Path Case of the Month:

73-year-old man with newly diagnosed prostate cancer

Jesi Kim, MS4

Harvard Medical School

Vignesh Shanmugam, MD

Department of Pathology

Angela Giardino, MD

Department of Radiology

Brigham & Women's Hospital



BRIGHAM HEALTH



BRIGHAM AND
WOMEN'S HOSPITAL



Patient Presentation

- Patient is a 73 year-old black man with new diagnosis of prostate cancer who presents for a staging MRI.
- History remarkable for 30 lb. unintentional **weight loss** over 6 months
- **Past Medical History:** Type 2 diabetes mellitus, glaucoma, hypertension, hyperlipidemia
- **Past Surgical History:** Refractive eye surgery
- **Social History:** Denies tobacco/alcohol/drugs
- **Labs:** PSA = 6.47 ng/mL (reference: 0 - 4.4)

ACR Appropriateness Criteria for clinically established intermediate-risk prostate cancer.

Variant 4: Clinically established intermediate-risk prostate cancer. Staging and/or surveillance.

| Radiologic Procedure | Rating | Comments | RRL* |
|--|--------|----------|------|
| MRI pelvis without and with IV contrast | 8 | | ○ |
| MRI pelvis without IV contrast | 7 | | ○ |
| MRI targeted biopsy prostate | 6 | | ○ |
| CT abdomen and pelvis with IV contrast | 6 | | ☼☼☼ |
| Tc-99m bone scan whole body | 6 | | ☼☼☼ |
| TRUS guided biopsy prostate | 5 | | ○ |
| CT abdomen and pelvis without IV contrast | 5 | | ☼☼☼ |
| TRUS prostate | 2 | | ○ |
| CT abdomen and pelvis without and with IV contrast | 2 | | ☼☼☼☼ |

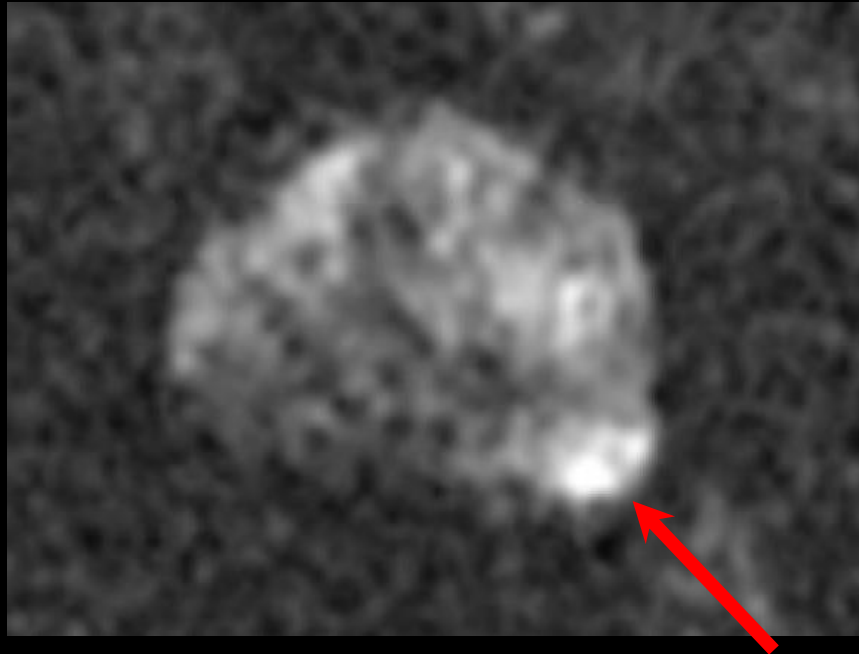Rating Scale: 1,2,3 Usually not appropriate; 4,5,6 May be appropriate; 7,8,9 Usually appropriate

***Relative Radiation Level**

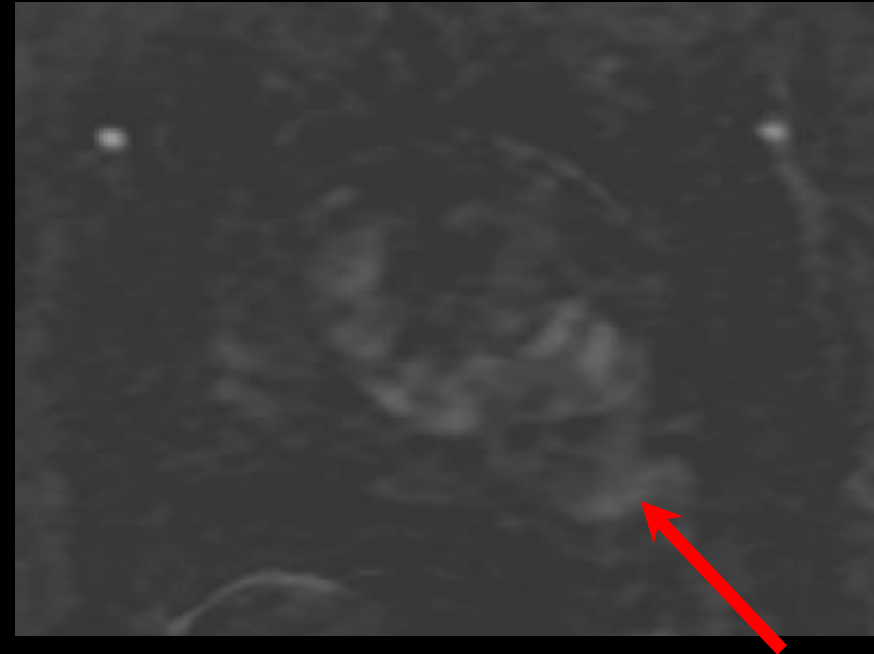MRI pelvis with and without contrast

Representative images:

Diffusion Weighted Image (DWI)



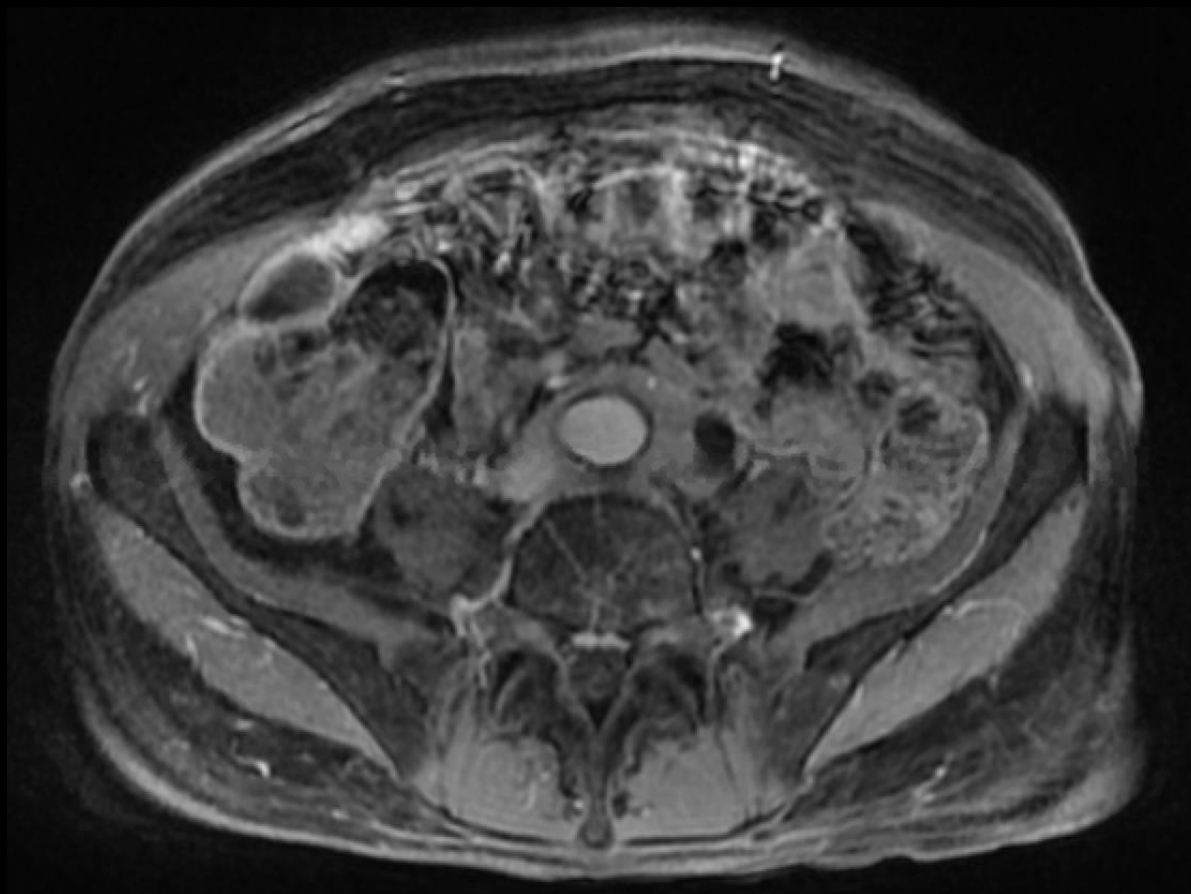
Dynamic Contrast Enhancement (DCE)



1.2 cm focal lesion in the peripheral zone that is isointense/mildly hyperintense on high b-value DWI and dynamic contrast enhancement positive. Lesion was classified as PI-RADS 4 – High (clinically significant cancer is likely to be present). Biopsy resulted in Gleason 3+4.

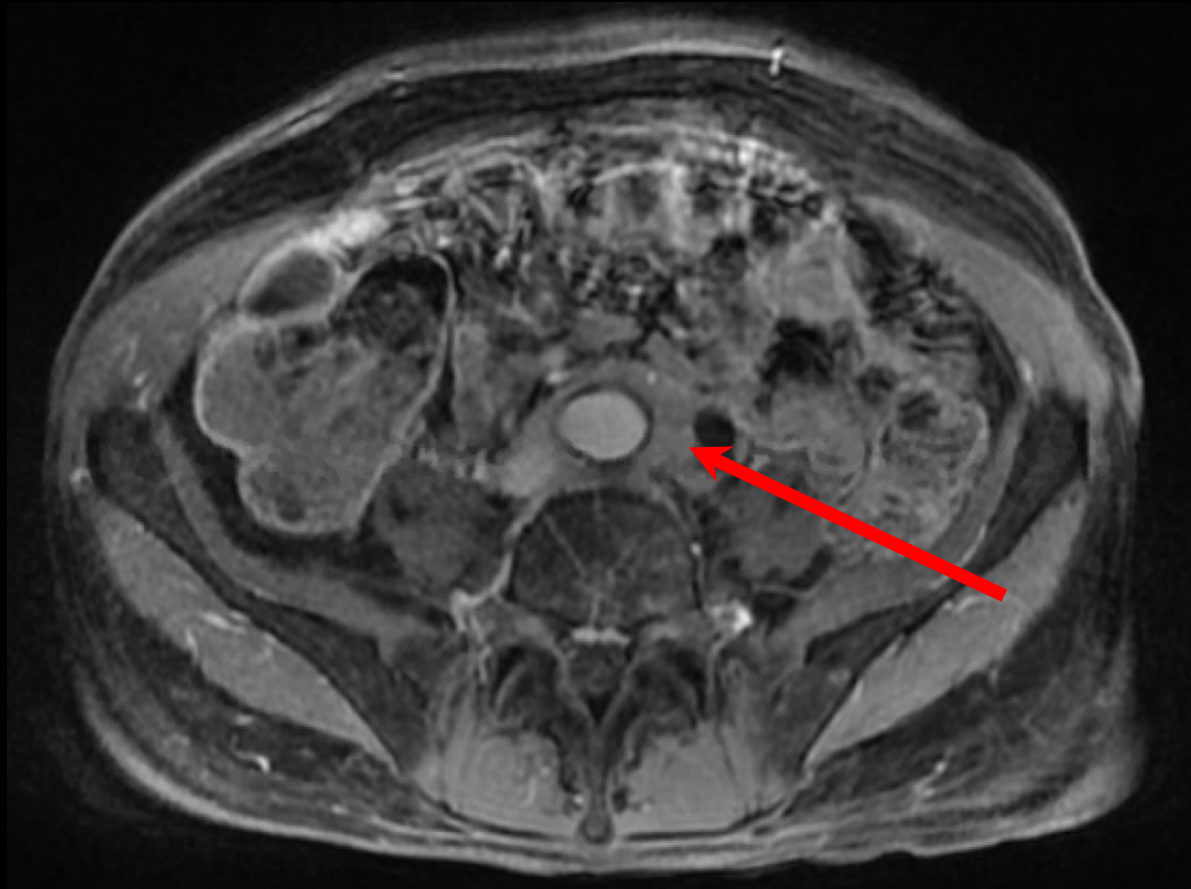MRI (unlabeled)

T1 fat sat



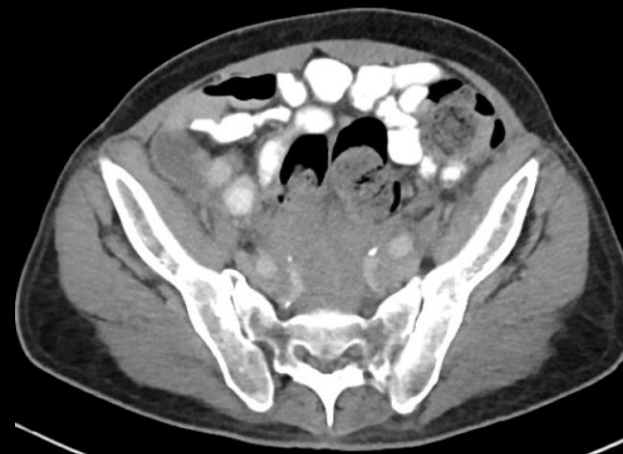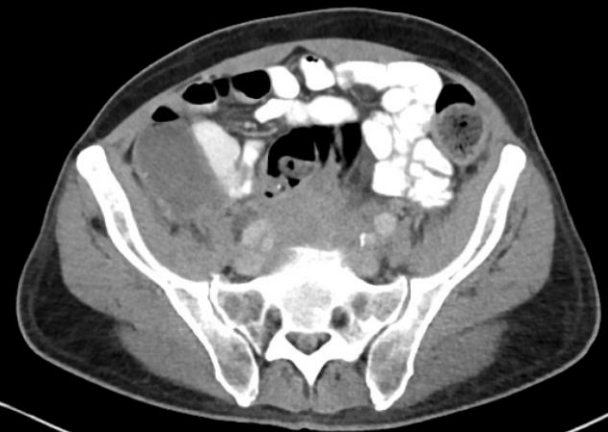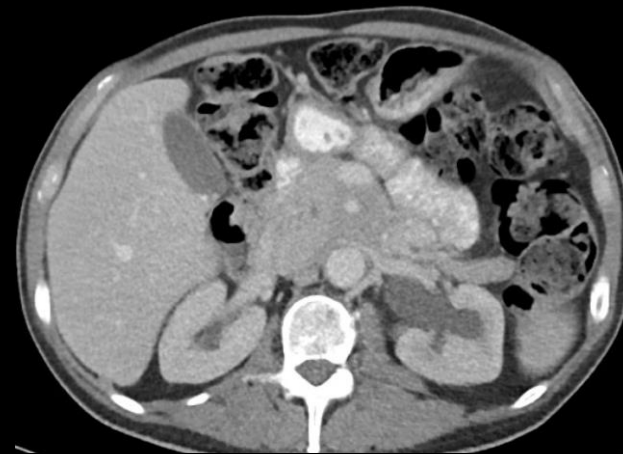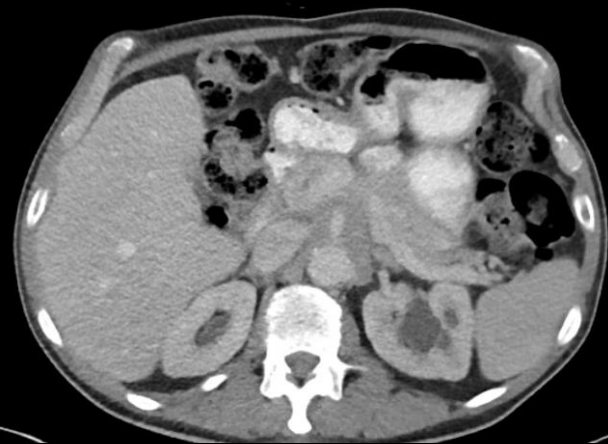MRI (labeled)

T1 fat sat



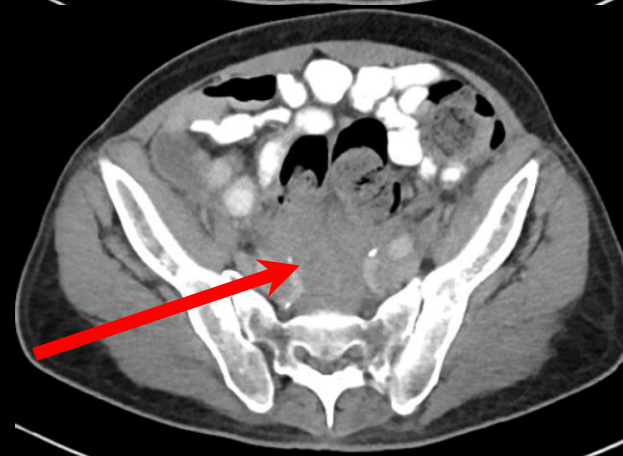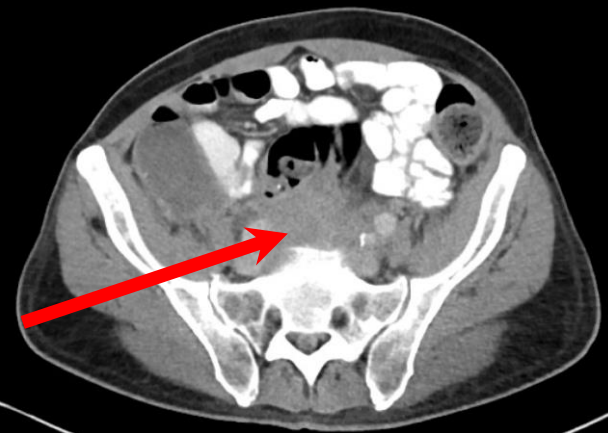
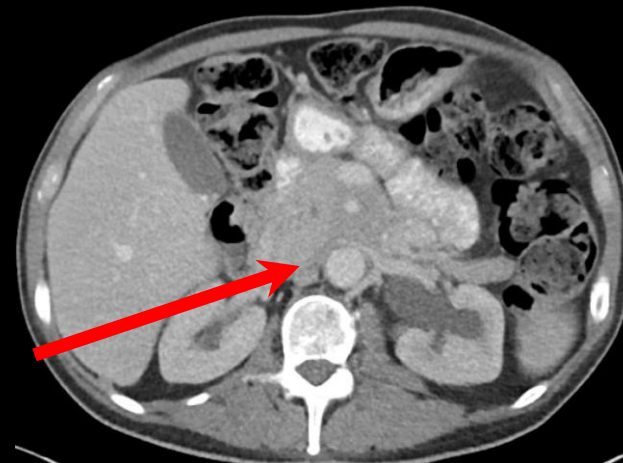
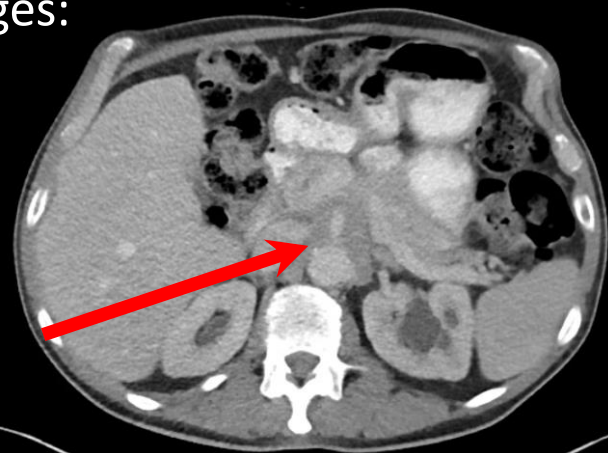
Incidentally noted abnormal para-aortic soft tissue. CT abdomen/pelvis was ordered to further evaluate.

CT abdomen/pelvis findings (unlabeled)



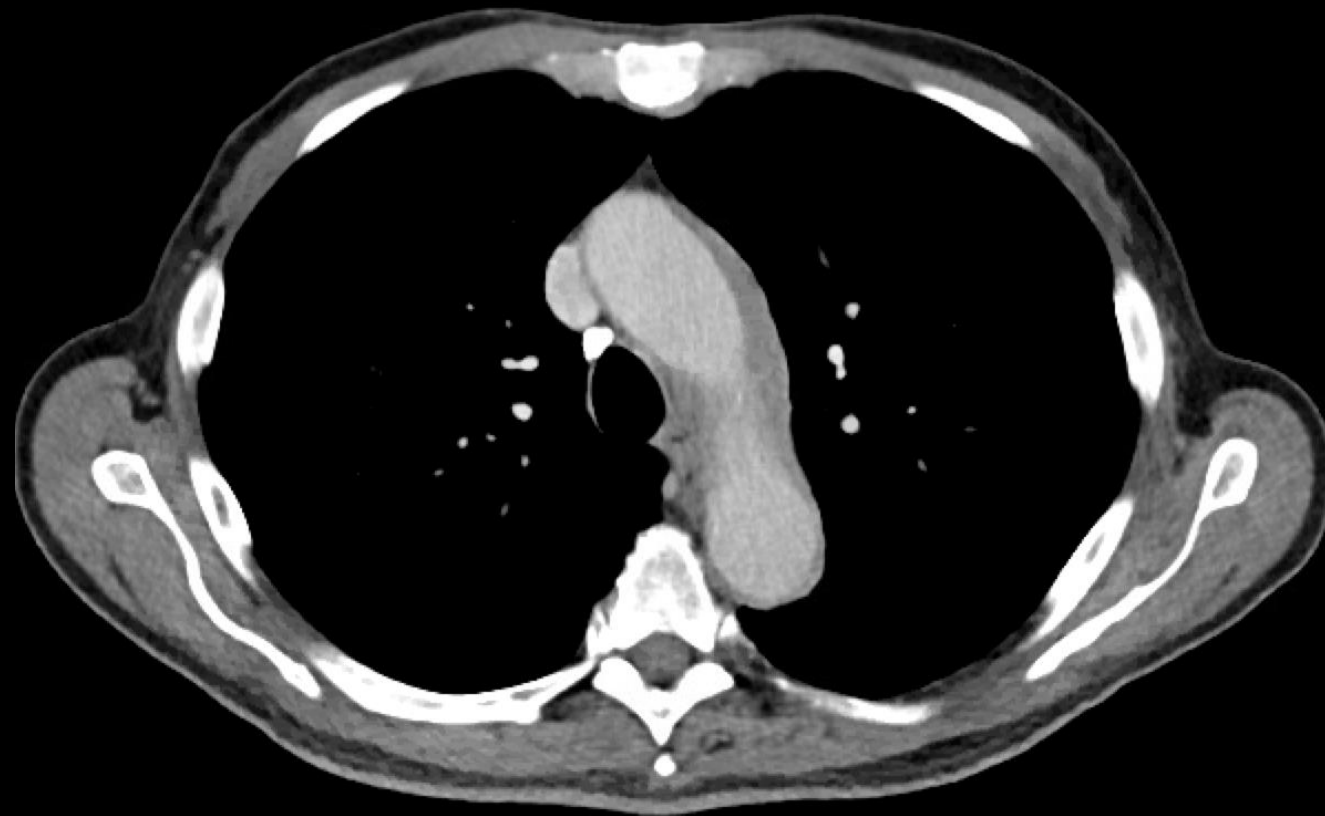
CT abdomen/pelvis findings (labeled)

Representative images:

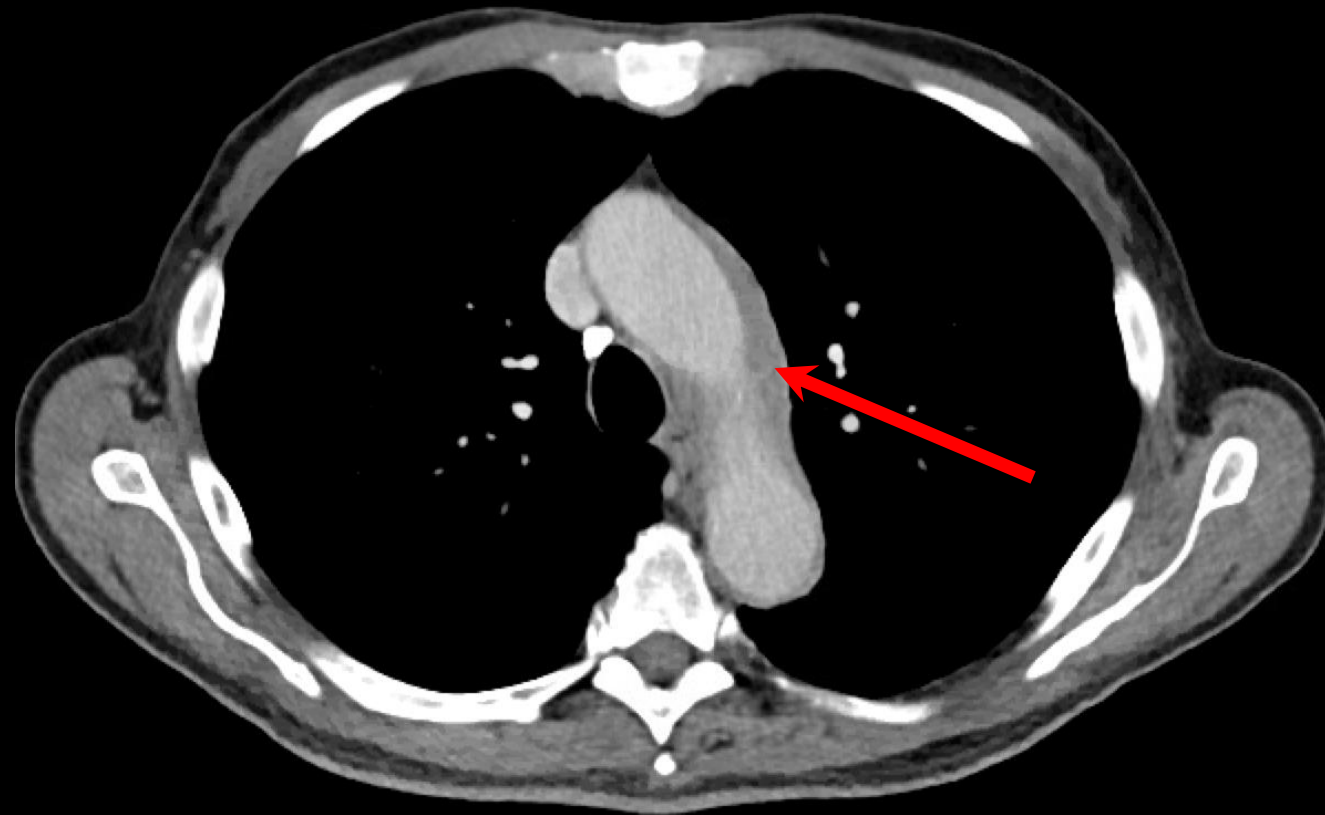


Ill-defined infiltrative soft tissue/adenopathy encasing the aorta, SMA, and common iliac vessels, extending to the presacral space.

CT chest findings (unlabeled)



CT chest findings (labeled)



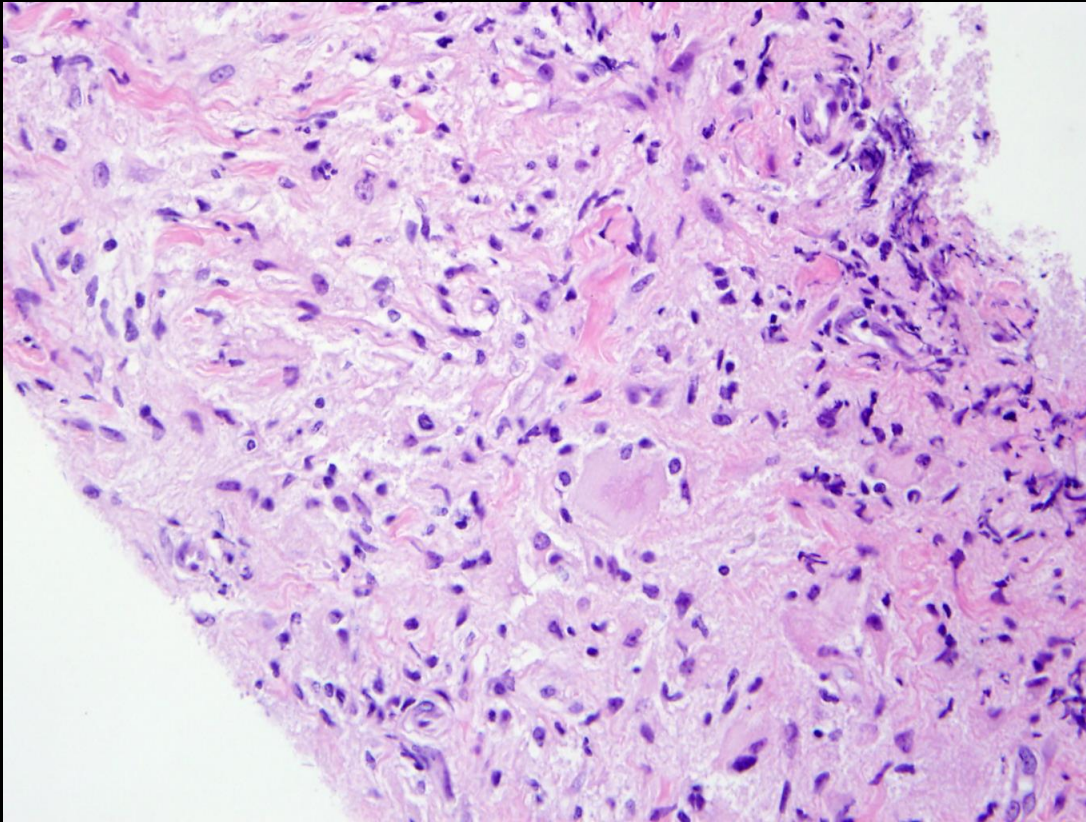
Abnormal soft tissue adjacent to the aortic arch

Differential Diagnosis:

- Lymphoma/lymphoproliferative disorder
- Metastatic disease
- Infectious/inflammatory:
 - Tuberculosis
 - Sarcoid
 - Castleman disease
- Erdheim-Chester disease
- Other rare etiologies

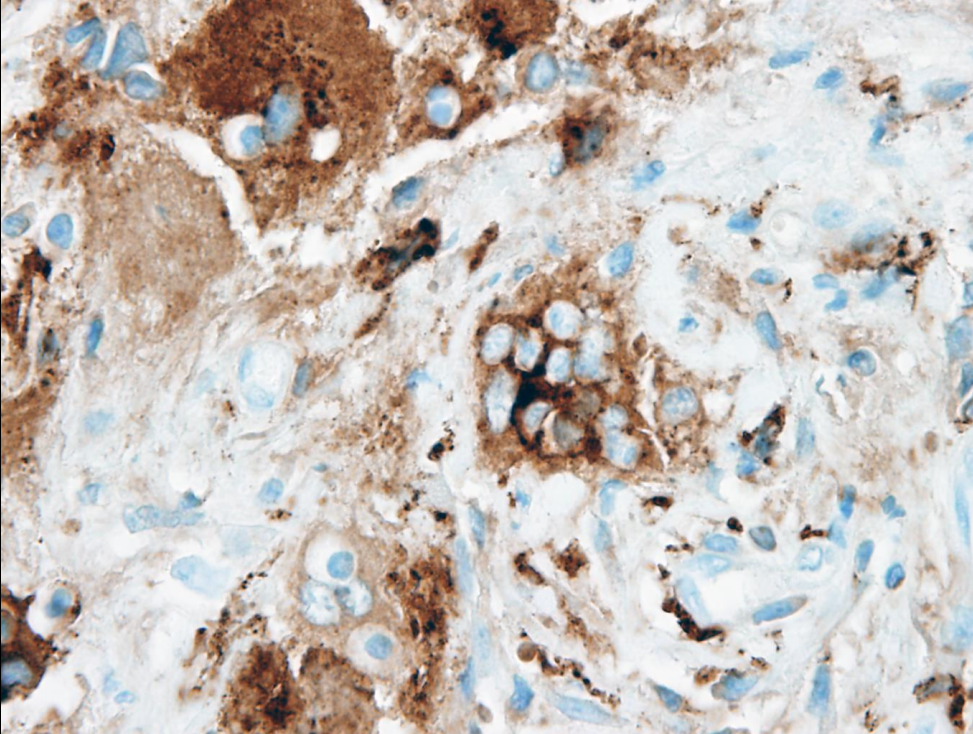
Because distribution and appearance were atypical for metastatic prostate cancer, presacral soft tissue biopsy was performed.

Histopathology



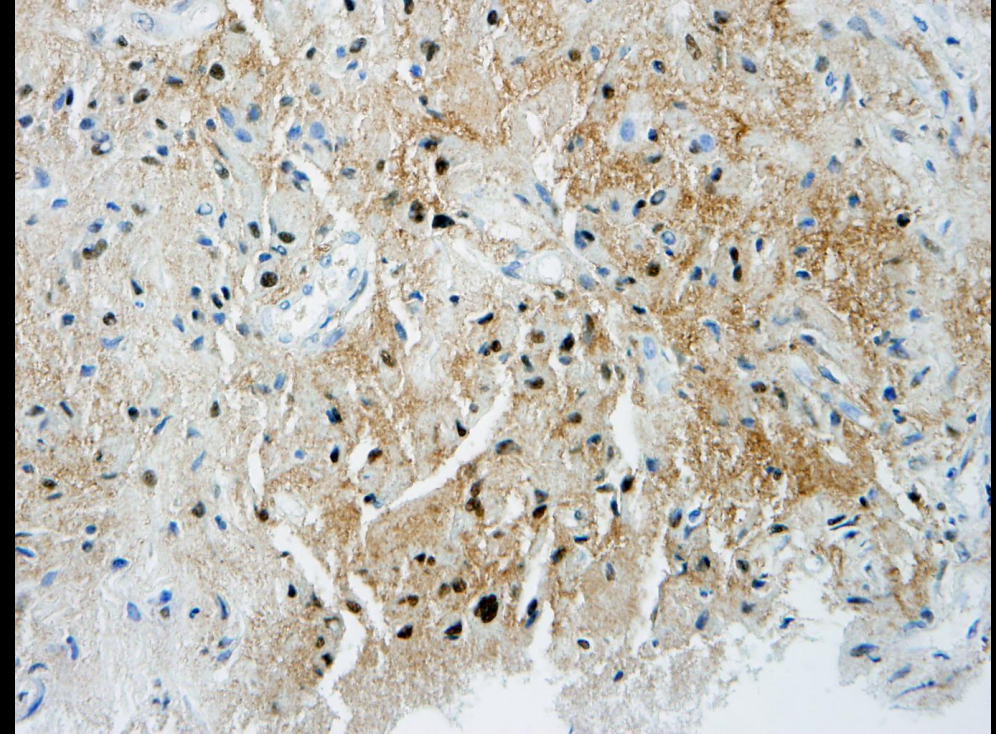
- Core biopsies showing an atypical histiocytic infiltrate involving fibrous tissue with scattered plasma cells. The histiocytes have irregular nuclei and voluminous eosinophilic cytoplasm.

Immunohistochemistry



CD163

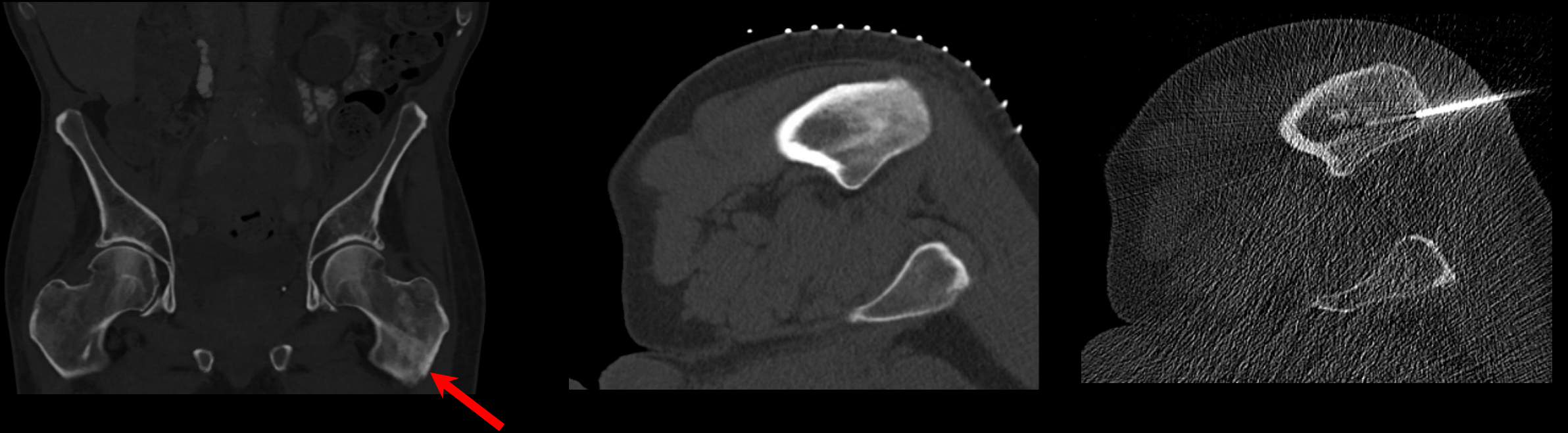
- Highlights emperipolesis (intact cell within the cytoplasm of another cell)



S100

- Expression on macrophages:

Final Diagnosis:
Rosai-Dorfman disease (RDD)



A few sclerotic bone lesions were also noted on the CT abdomen/pelvis. For example, proximal left femur (red arrow). CT guided biopsy was performed. Pathology results consistent with involvement by RDD.

Case Discussion

- RDD is a rare non-Langerhans cell reactive histiocytic disorder first described in 1969.
- More descriptively called sinus histiocytosis with massive lymphadenopathy
- RDD is a result of infiltration of histiocytes in the sinuses that allow for the passage of lymph (sinus histiocytosis) or extranodal tissues.
- The defining feature of the disease is histiocyte emperipolesis, a nondestructive phagocytosis of lymphocytes or plasma cells.

Case Discussion

- Extranodal involvement has been noted to occur in 43% of cases, most commonly involves the head/neck, skin, and bones.
- Extranodal RDD has a higher tendency of relapsing course and affects older individuals
- Etiology is unknown, but it is thought to be non-neoplastic
- Infection (viruses such as EBV), immunodeficiency, or autoimmunity may have a role in pathogenesis.

Case Discussion

Epidemiology

- Affects males more than females
- Individuals of West African and Caribbean descent are more often affected
- Usually young adults with mean age of 20
- Uncommon disease

Signs and symptoms

- Varies greatly depending on extent of disease and specific organ system affected
- Most often presents with nonspecific painless cervical lymphadenopathy
- Other symptoms such as fever, pallor, unintended weight loss, night sweats
- Can also present in any extranodal site, most commonly in the skin, soft tissue, and bones
- Lab: leukocytosis and elevated ESR

Management and Treatment

- Spontaneous remission typically occurs in the classic head and neck nodal form seen in younger patients (< 20 years old): treatment is only advised for symptomatic patients or patients with vital organ involvement
- Symptom driven treatment
- First line treatment is surgical removal of histiocytic lesion
- For incomplete resection or disseminated disease, may consider:
 - Steroids
 - Alpha-interferon
 - Chemotherapy
 - Radiation

References

- American College of Radiology. ACR Appropriateness Criteria for Prostate Cancer—Pretreatment Detection, Surveillance, and Staging. Reston, VA: American College of Radiology, 2016.
- Zaveri J., La Q., Yarmish G., Neuman J. (2014). “More than Just Langerhans Cell Histiocytosis: A Radiologic Review of Histiocytic Disorders,” *Radiographics*; 34(7):2008-2024.
- McClain K.L. (2019). “Peripheral lymphadenopathy in children: Etiology.” In: UpToDate, Post TW (Ed), UpToDate, Waltham, MA.
- Alba O., et al. (2018). “Consensus recommendations for the diagnosis and clinical management of Rosai-Dorfman-DeStombes disease,” *Blood*; 131:2877-2890.
- Dalia S., et al. (2014). “Rosai–Dorfman Disease: Tumor Biology, Clinical Features, Pathology, and Treatment,” *Cancer Control*; 21 (4): 322-327
- Mar W.A., et al. (2017) “Rosai-Dorfman Disease: Manifestations Outside of the Head and Neck,” *AJR*; 208: 721-732