

AMSER RAD PATH Case of the Month:

3 yo M with rectal prolapse and hematochezia

Jackson Pearce, MS4

Dr. Jeanne Hill, MD

Dr. Laura Spruill, MD

Medical University of South Carolina

Patient Presentation

3 yo M presents to Peds GI clinic w/ rectal prolapse and hematochezia

PMHx: none

History: 2 months of scant bright red blood per rectum; 1 ED visit for episode of rectal prolapse - reduced in ED, patient discharged on Miralax, suspicion for intussusception but no work up

ROS: (+) Abdominal pain/discomfort, (-) Anorexia, Reflux, Emesis

PE: Normal

In clinic:

-Abdominal radiograph demonstrated mild to moderate stool burden, otherwise normal

-Continued Miralax for stool softening with option for enema



Patient Course

1 Week Later

Patient bowel movements consist of "sandy, gritty" stool that is like gravel. Peds GI recommends an enema performed at home, and patient has massive blowout with frank blood. Patient presents to ED.

ED Course:

CC: Bloody diarrhea

ROS: (+) Worsening and increased frequency of abdominal pain, Anorexia

PE: no rectal prolapse, no blood seen in rectum/diaper

Patient Course

ED Course:

Labs:

- Hemoglobin/Hematocrit: 10.1/30.8
- CMP – wnl
- CRP – 0.03
- ESR — 3
- Gliadin IgA/IgG – wnl
- TTG IGA/IgG – wnl
- IgA — wnl
- Lipase — wnl

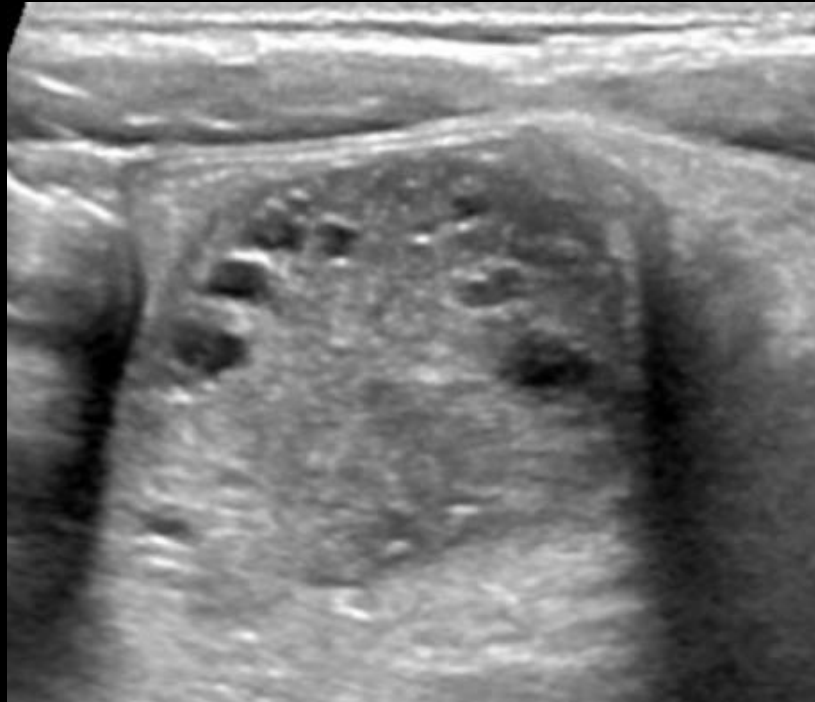
Differential: Intussusception, Celiac Dz

What Imaging Should We Order?

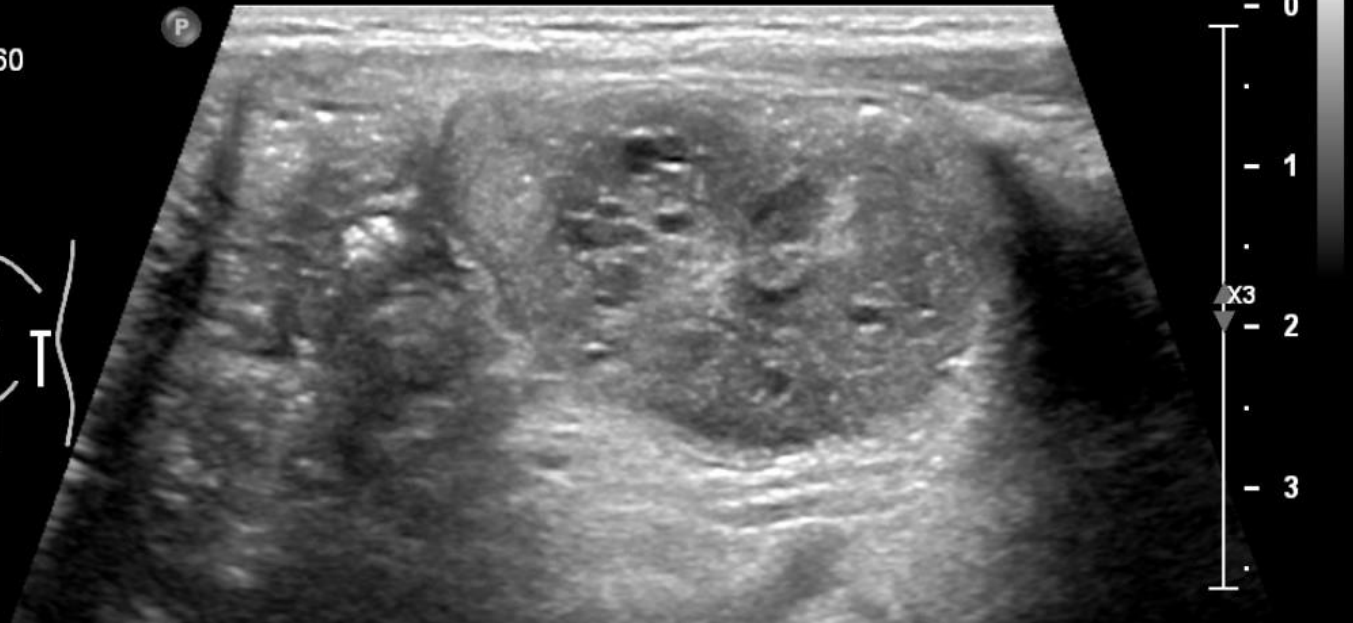
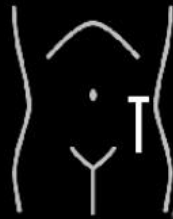ACR Appropriateness Criteria

No current ACR criteria for suspected intussusception; however, medical literature agrees that ultrasonography remains the first choice diagnostic test for suspected intussusception.

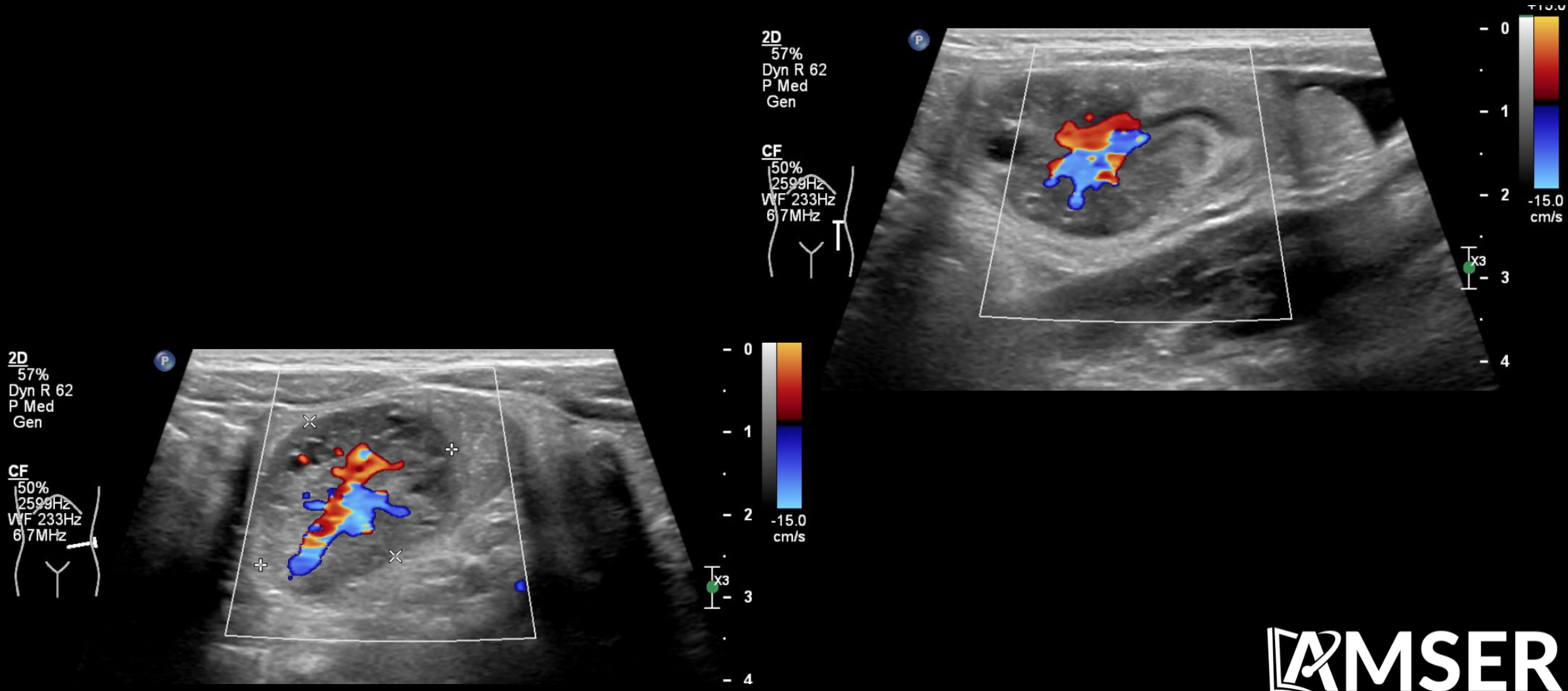
Abdominal Ultrasound



2D
49%
Dyn R 60
P Med
Gen

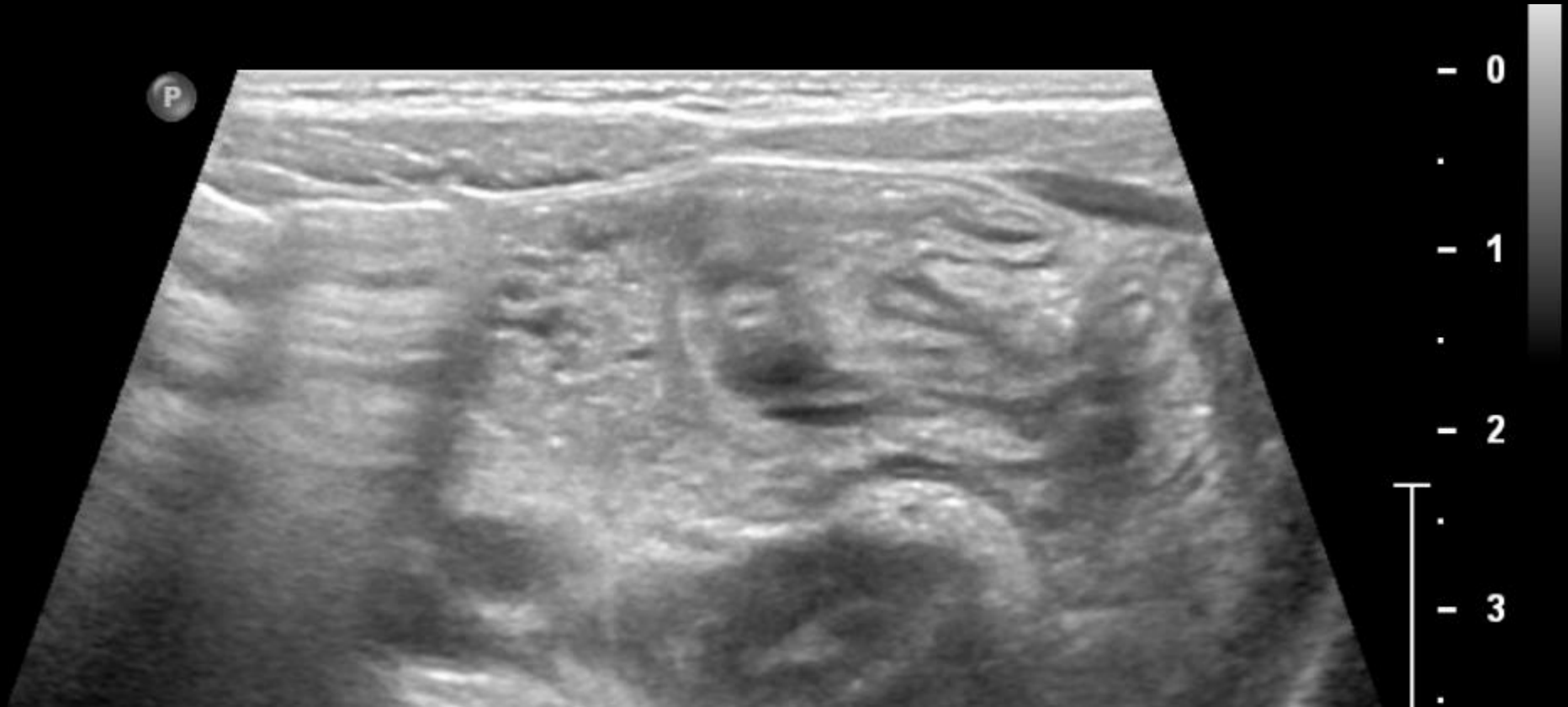
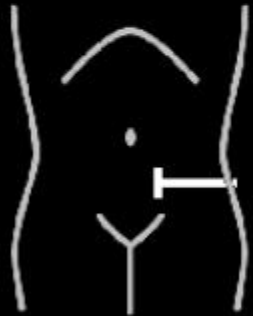


Abdominal Ultrasound with Doppler

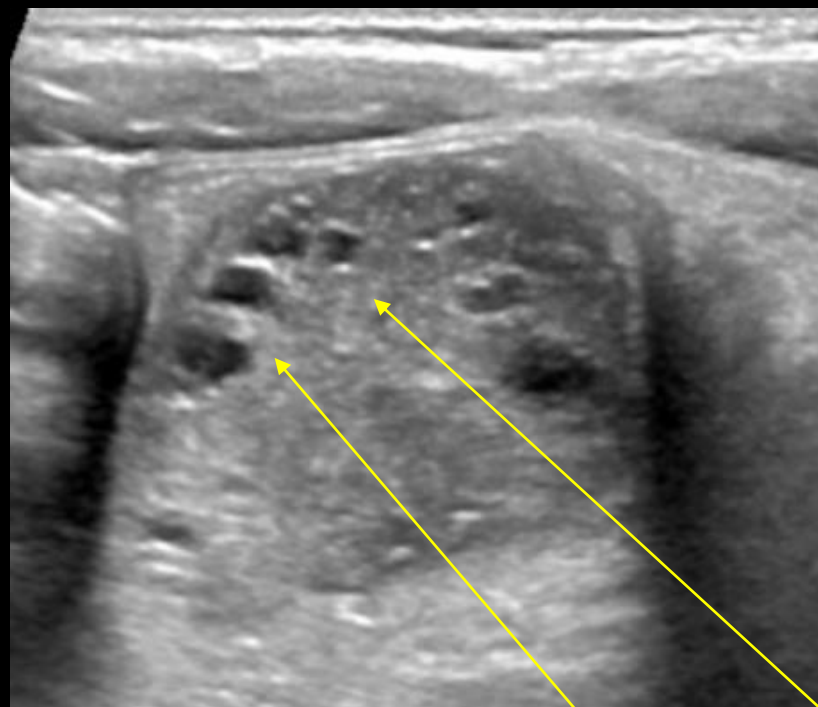


Abdominal Ultrasound

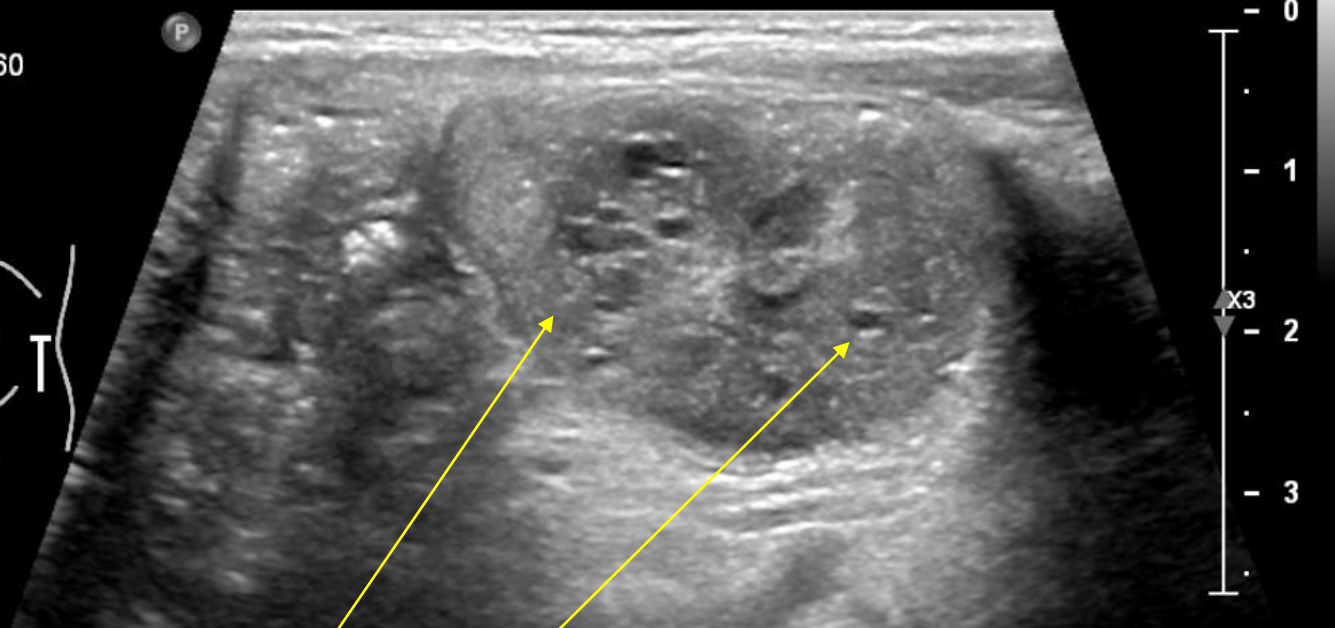
2D
51%
Dyn R 60
P Med
Gen



Abdominal Ultrasound – 2cm polyp



2D
49%
Dyn R 60
P Med
Gen



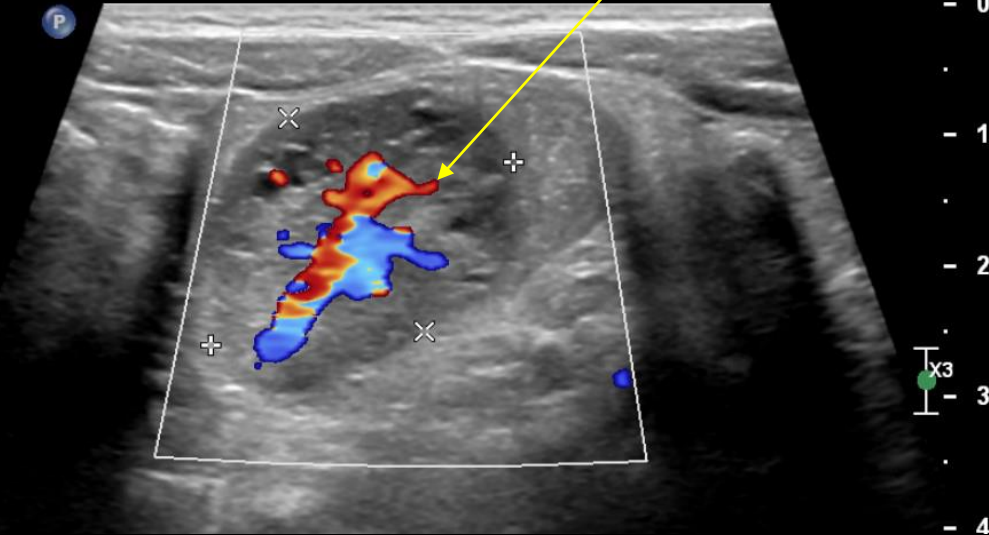
Cystic spaces in
intraluminal colonic
mass at splenic flexure

Abdominal Ultrasound with Doppler

Yellow arrows:
mass with central vasculature
affixed to colonic wall by a pedicle

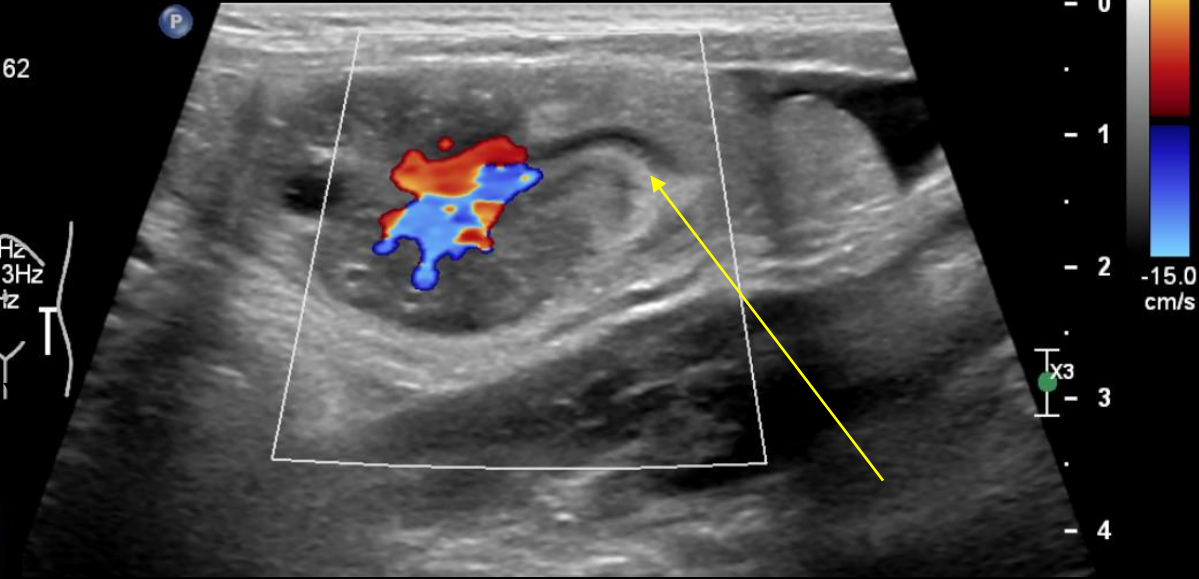
2D
57%
Dyn R 62
P Med
Gen

CF
50%
2599Hz
WF 233Hz
6.7MHz



2D
57%
Dyn R 62
P Med
Gen

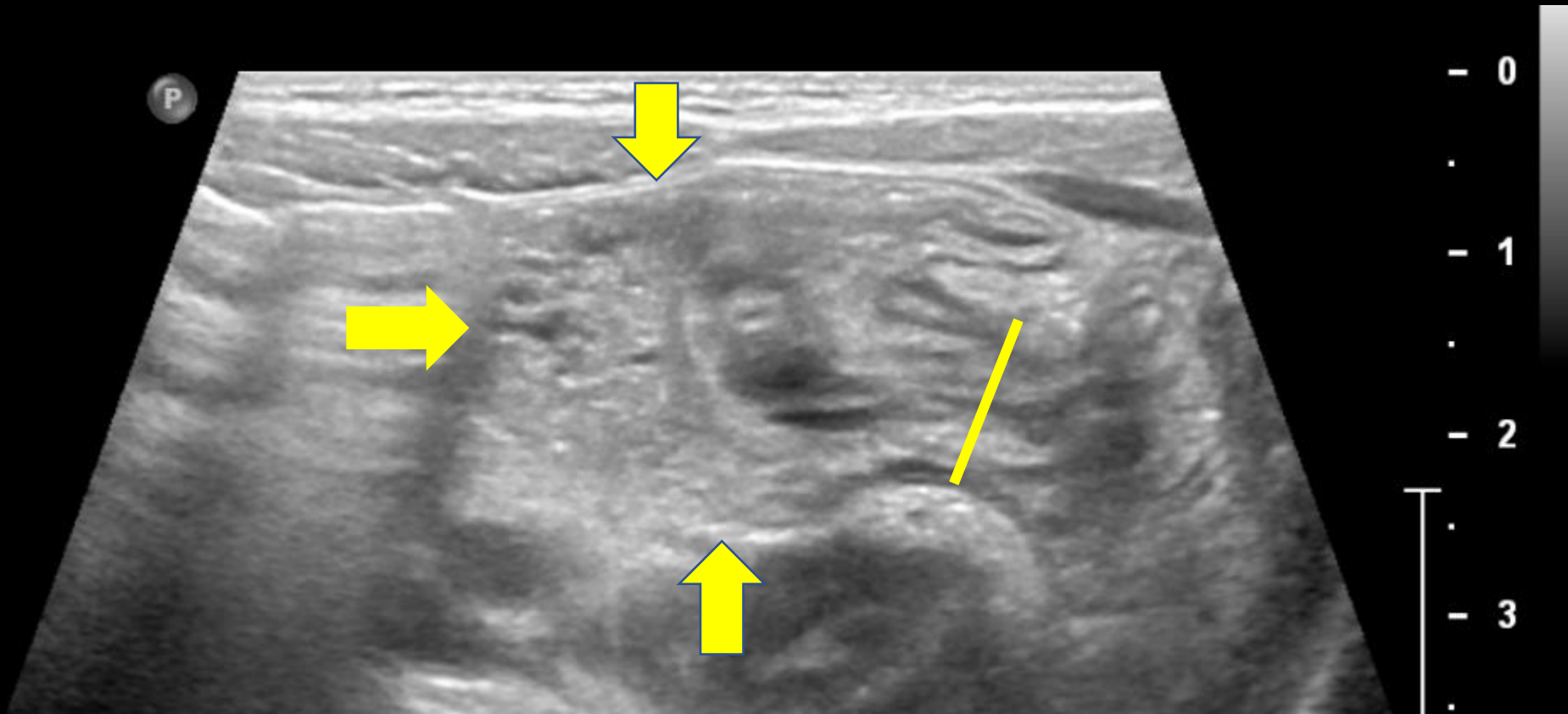
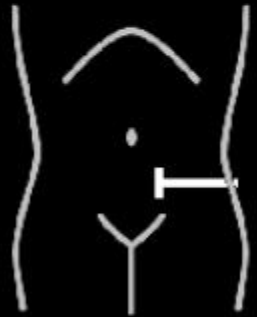
CF
50%
2599Hz
WF 233Hz
6.7MHz



Central pedicle of
pedunculated polyp

Abdominal Ultrasound - 2cm rectosigmoid polyp

2D
51%
Dyn R 60
P Med
Gen



The Yellow Line demarcates the pedicle or stalk at the base of the pedunculated polyp (arrowheads) - "mushroom" sign

Patient Course

ED Course: Working Diagnosis: intraluminal juvenile polyp

Patient discharged with follow up with Peds GI for sigmoidoscopy and polypectomy and return precautions for signs of worsening anemia

3 days later

Patient has persistent anorexia since discharge from the ED, bloody bowel movement, and episode of severe abdominal pain. Patient presents to ED with repeat rectal prolapse.

ED Course:

- Rectal prolapse reduced in ED
- Admitted for bowel prep and colonoscopy

ACR Appropriateness Criteria¹

Variant 1:

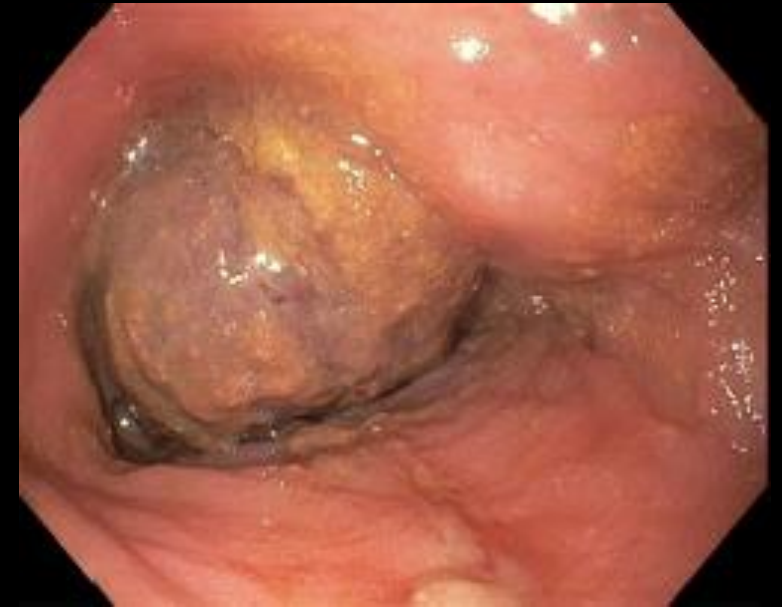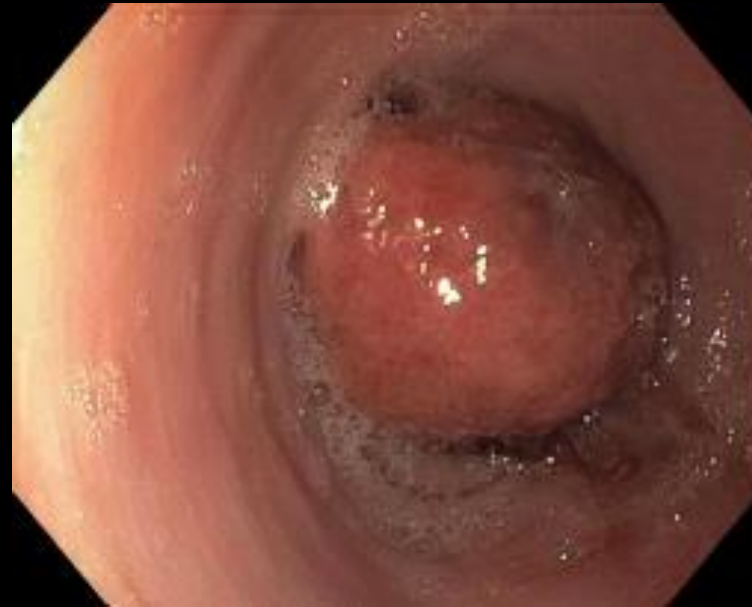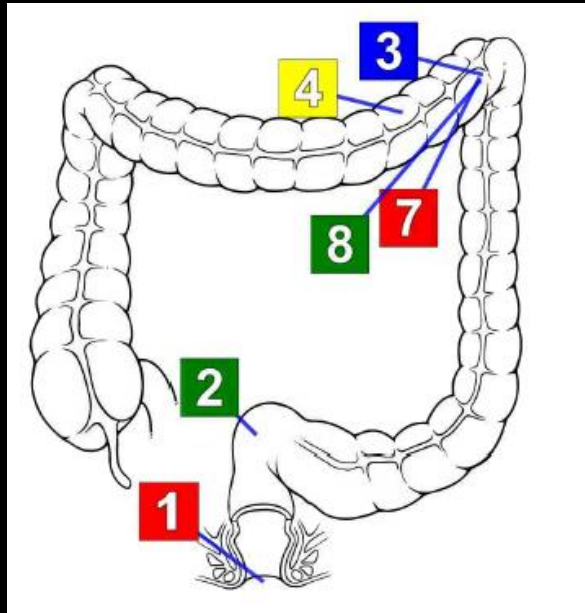
Lower gastrointestinal tract bleeding. Active bleeding clinically observed as hematochezia or melena in a hemodynamically stable patient. Next step.

Procedure	Appropriateness Category
CTA abdomen and pelvis without and with IV contrast	Usually Appropriate
Diagnostic/therapeutic colonoscopy	Usually Appropriate
RBC scan abdomen and pelvis	Usually Appropriate
Transcatheter arteriography/embolization	May Be Appropriate
MRA abdomen and pelvis without and with IV contrast	Usually Not Appropriate
Surgery	Usually Not Appropriate

Planned procedure following visualized polyp on ultrasound



Colonoscopy Findings



3 Splenic Flexure : Single Polyp

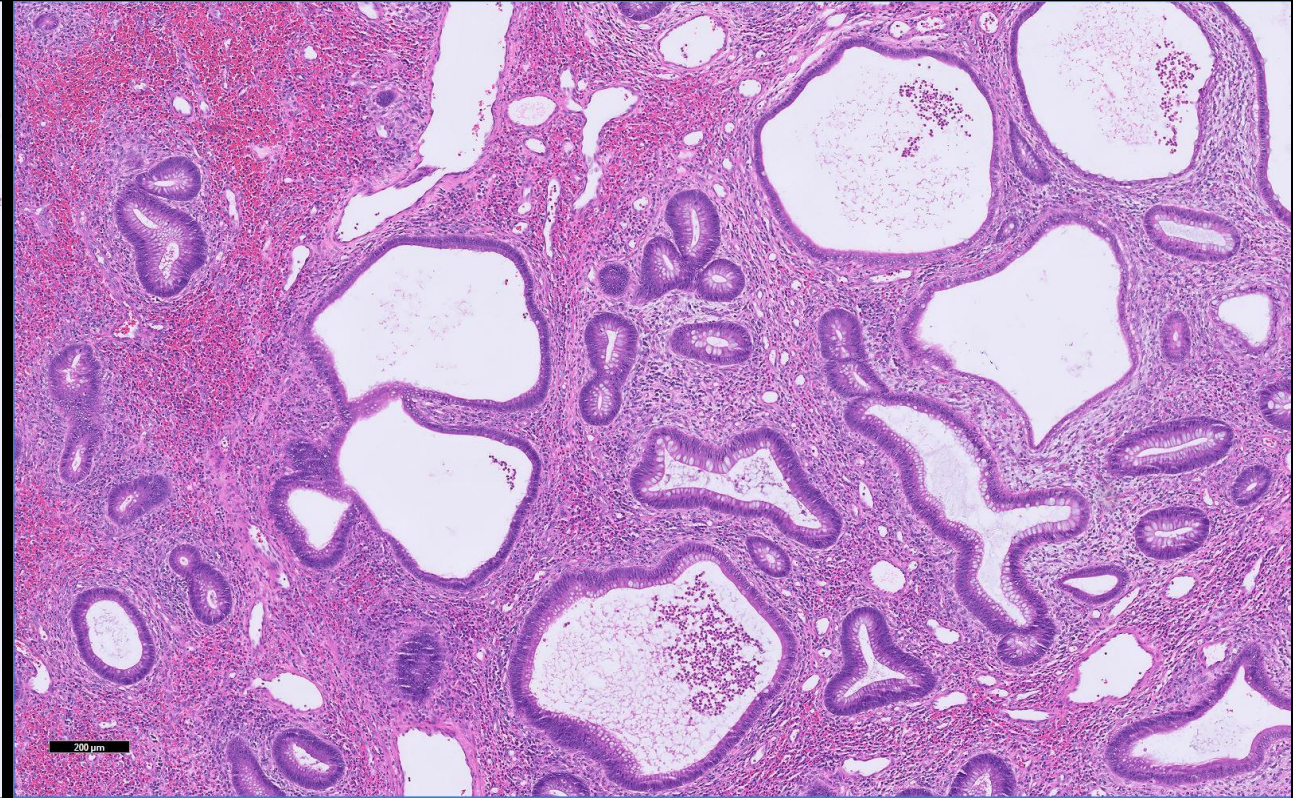
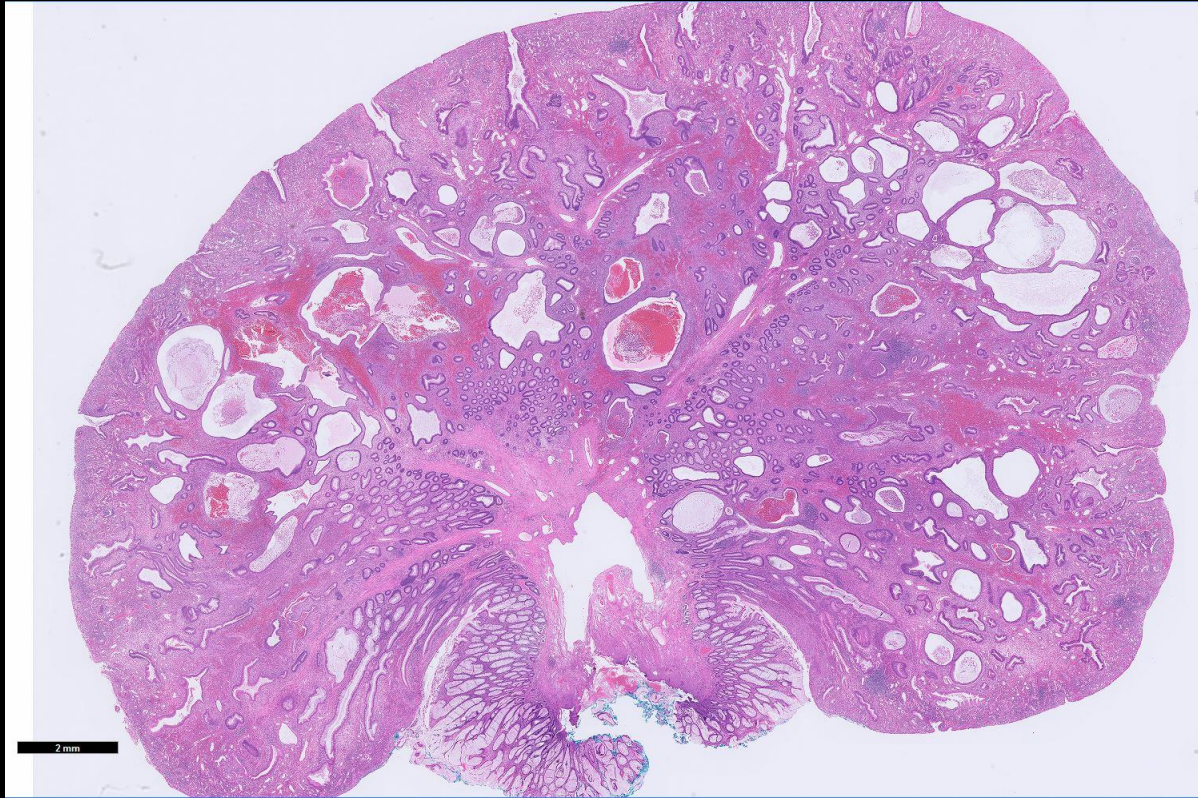
Colonoscopy Findings

Perianal and digital rectal examinations were normal.

One 35 mm pedunculated polyp identified at the splenic flexure and successfully removed with a hot snare and sent for pathology.

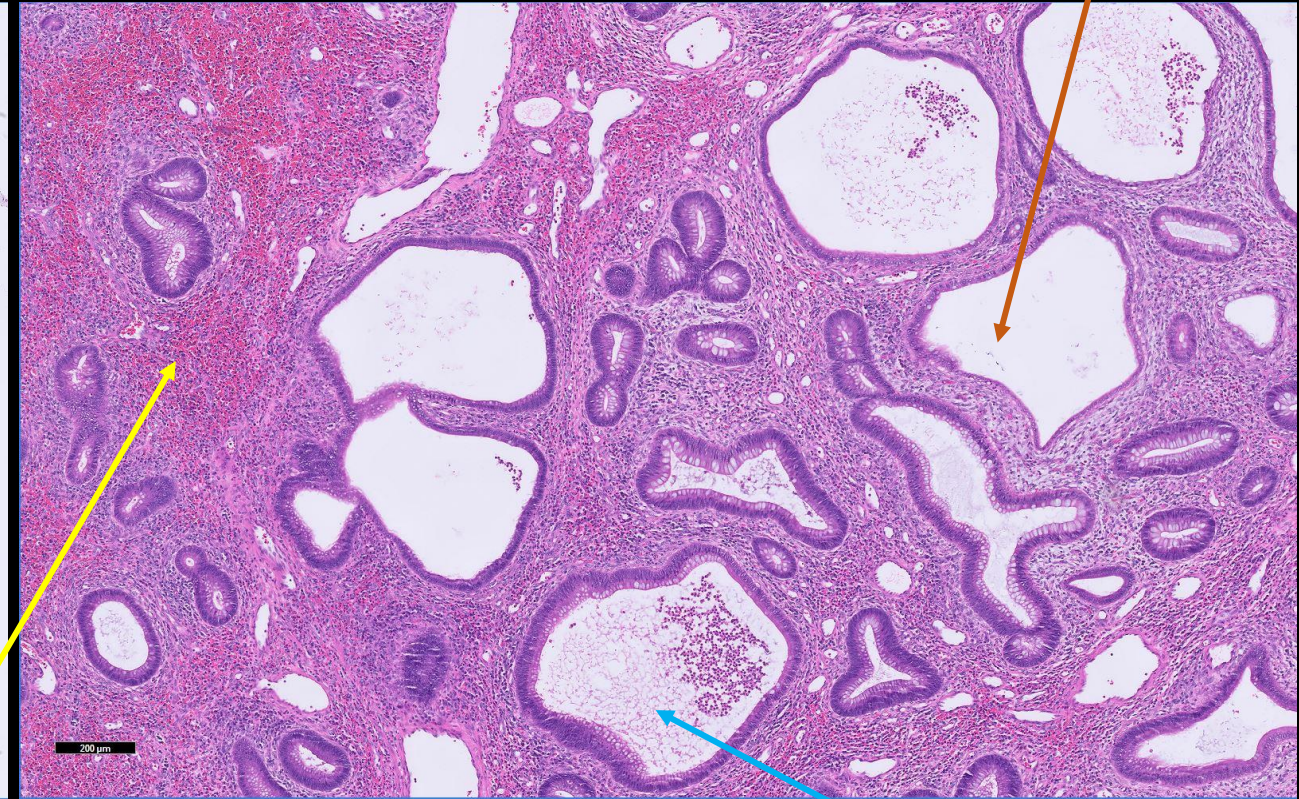
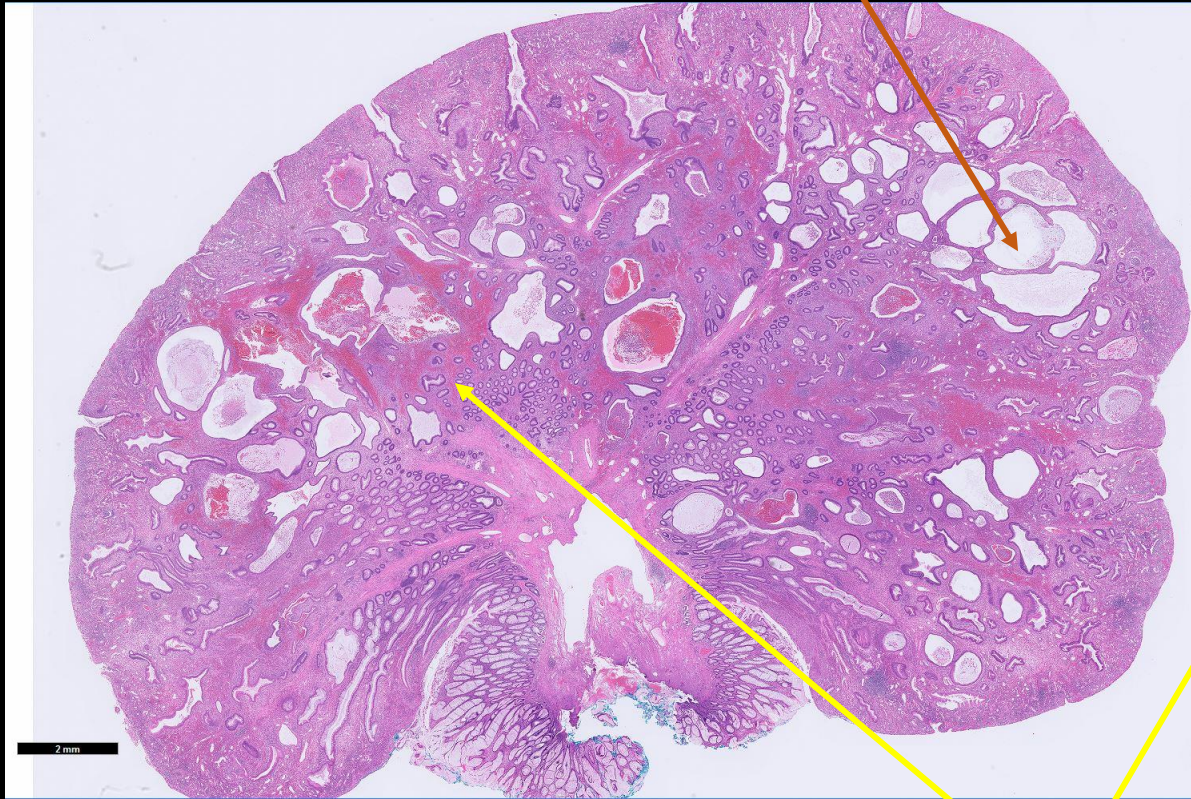
Rectum, sigmoid, and transverse colon were normal.

Pathology



Nota Bene: dilated glands seen on histopathology correlate with cysts visualized on abdominal ultrasound

Pathology



- Pathology demonstrates an abundance of **edematous lamina propria with inflammatory cells** and **cystically dilated glands** lined by epithelium with reactive changes (non-neoplastic)
- **Dilated glands** filled with **mucous, inspissated inflammatory debris, protein, or blood**

Protein

Final Dx:

Juvenile Polyp – Benign Hamartoma

Juvenile Polyps – Clinical Pearls

- Typically occur between ages 2-10, with peak at 3-4 yo²
- Presents with painless rectal bleeding, w/ or w/o mucous, and occasionally lower abdominal pain³
- Generally pedunculated (versus sessile)
- 60-80% in rectosigmoid flexure²
- Pathology: benign hamartoma (85%), adenoma (<10%), hyperplastic (3%)⁴

Juvenile Polyps – Imaging Characteristics^{5,6}

- **Common ultrasound features:**

- Isolated intraluminal nodular or massive protrusion within bowel
- Nodule is hypoechoic with a hyperechoic layer
- Cysts of varying sizes (can be described as mesh-like)
- Pedicle that connects polyp creates "mushroom" sign on ultrasound
- Color doppler helps demonstrate the vascular supply of polyp

- **Diagnostic utility of ultrasound:**

- A retrospective study of 288 patients found that ultrasound identified 64.74% of solitary polyps without colon preparation; following colon preparation, 94.96% of solitary polyps were identified via ultrasound
- The sensitivity & specificity of US following glycerine enema were 94.96% and 100%, respectively

Juvenile Polyps – Pathological Subtypes^{4,7,8,9}

- **Benign Hamartoma (85%)**

- Most common subtype
- Characterized by edematous lamina propria with inflammatory cells and cystically dilated, irregular glands lined by epithelium with non-neoplastic reactive changes. As seen on previous pathology slides, glands can contain mucous, inspissated inflammatory debris, protein, or blood (which can be pushed into glands procedurally)
- Patients with a single benign hamartoma have an estimated recurrence rate of 17%

- **Adenoma (<10%)**

- Characterized by low grade cytological dysplasia
- More common in older children and adolescents
- More common in the setting of juvenile polyposis syndromes or chromosomal abnormalities
- May require more frequent screening via colonoscopy/sigmoidoscopy

- **Hyperplastic (3%)**

- Most rare subtype
- Characterized by increased surface epithelium, no cystic dilation, glands are vertically arranged and not complex

Patient Course

- Patient recovered well from polyp removal and was discharged with Miralax for continued constipation
- Patient had 1 later episode of blood in stool (following a URI) and several instances of abdominal pain and straining with bowel movements
- A colonoscopy completed over 1 year later demonstrated no recurrence and normal pathology results
- Given isolated single polyp and lack of recurrence, screening guidelines do not recommend further follow up

References

- ¹ACR Appropriateness Criteria: Lower Gastrointestinal Tract Bleed
- ²Lee BG, Shin SH, Lee YA, Wi JH, Lee YJ, Park JH. Juvenile polyp and colonoscopic polypectomy in childhood. *Pediatr Gastroenterol Hepatol Nutr*. 2012;15(4):250-255. doi:10.5223/pghn.2012.15.4.250
- ³Campbell AM, Sugarman I. Does painless rectal bleeding equate to a colonic polyp? *Arch Dis Child*. 2017;102(11):1049-1051. doi:10.1136/archdischild-2016-311245
- ⁴Thakkar K, Alsarraj A, Fong E, Holub JL, Gilger MA, El Serag HB. Prevalence of colorectal polyps in pediatric colonoscopy. *Dig Dis Sci*. 2012;57(4):1050-1055. doi:10.1007/s10620-011-1972-8
- ⁵Zhang Y, Li SX, Xie LM, et al. Sonographic diagnosis of juvenile polyps in children. *Ultrasound Med Biol*. 2012; 38(9):1529-1533. doi:10.1016/j.ultrasmedbio.2012.05.018
- ⁶Qu NN, Lui RH, Shi L, Cao XL, Yang YJ, Li J. Sonographic diagnosis of colorectal polyps in children: Diagnostic accuracy and multi-factor combination evaluation. *Medicine (Baltimore)*. 2018;97(39):e12562. doi:10.1097/MD.00000000000012562
- ⁷Fox VL, Perros S, Jiang H, Goldsmith JD. Juvenile polyps: recurrence in patients with multiple and solitary polyps. *Clin Gastroenterol Hepatol*. 2010;8(9):795-799. doi:10.1016/j.cgh.2010.05.010
- ⁸Kay M, Eng K, Wyllie R. Colonic polyps and polyposis syndromes in pediatric patients. *Curr Opin Pediatr*. 2015;27(5):634-641. doi:10.1097/MOP.0000000000000265
- ⁹Rouse RV. Juvenile Polyp of the Gastrointestinal Tract. *Stanford Surgical Pathology Criteria*. surgpathcriteria.stanford.edu/gitumors/juvenile-polyp/printable.html.