

AMSER RAD PATH Case of the Month: Adrenal Mass

Bianca Radut, OMS IV

Lake Erie College of Osteopathic Medicine

Matthew Hartman, MD

Department of Radiology

Cody Marshall, DO, PGY-2

Department of Pathology

Kossivi Dantey, MD

Department of Pathology

Suzanne Schiffman, MD

Surgical Oncology



Patient Presentation

HPI: 60 y.o. male presented to local OSH ED after an altercation resulting in fall on concrete with rib injury. At that time he underwent CT of the chest which showed incidental finding of right adrenal mass.

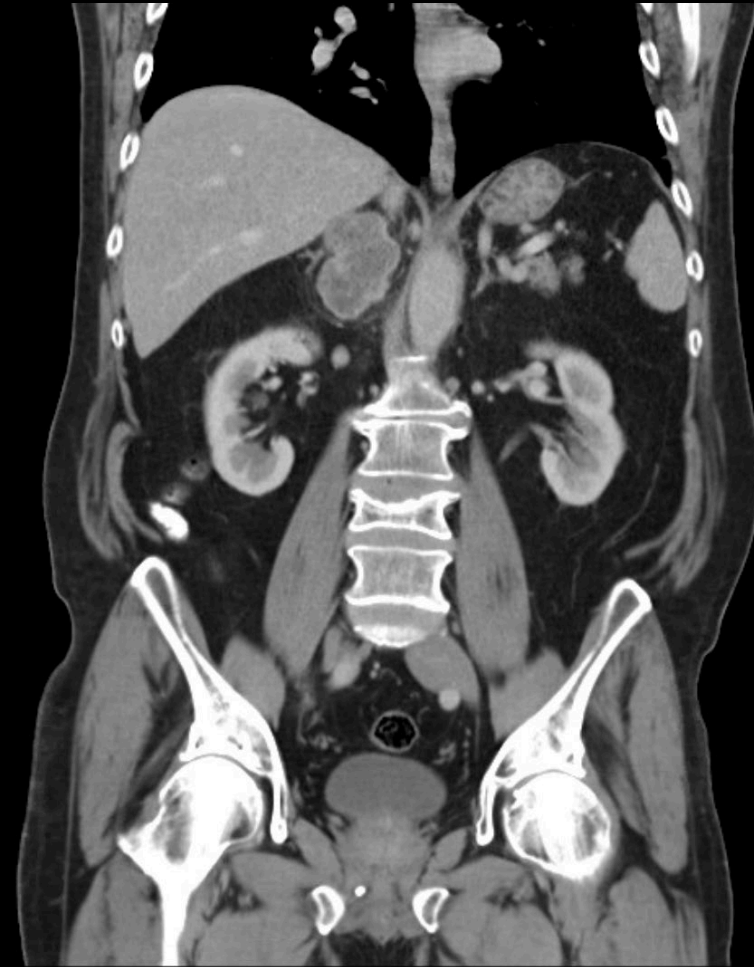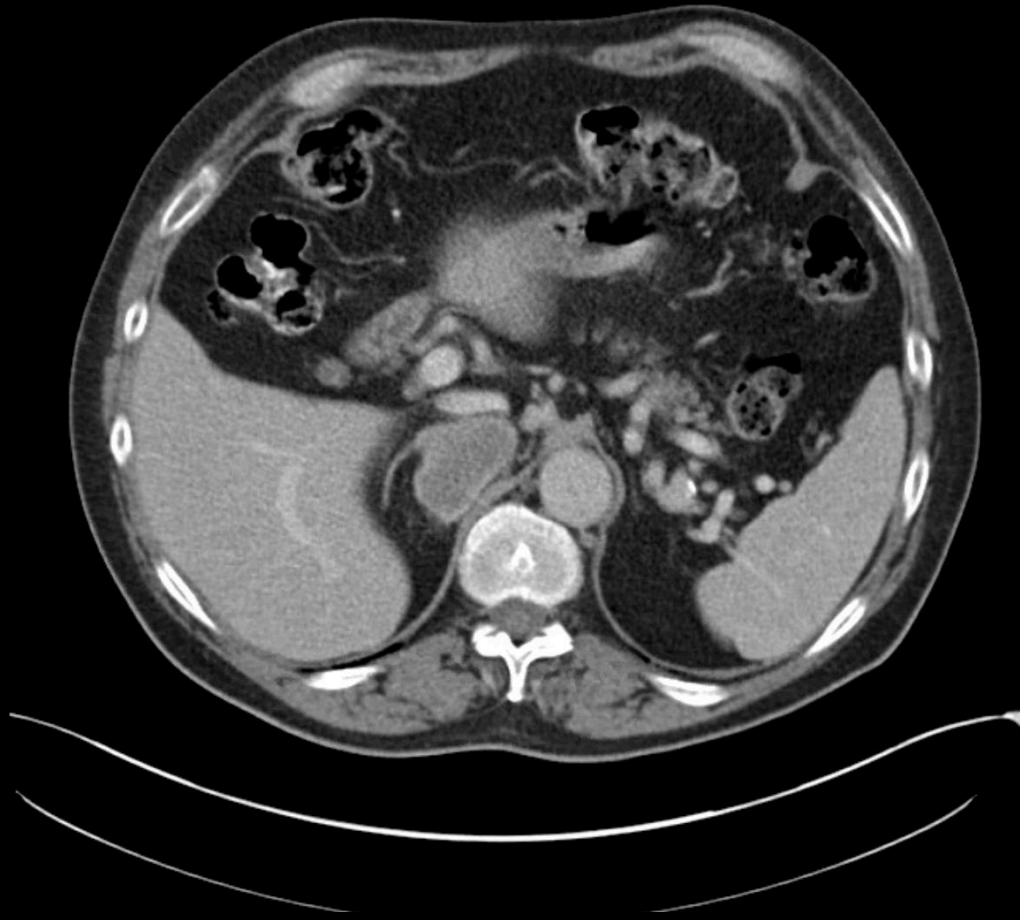
- PMHx: diverticulosis, gout, olecranon bursitis, mild obesity
- PSx: None
- FHx: colon cancer (mother)
- Meds: None
- Social: Occasional alcohol use ,denies tobacco or recreational drug use
- V/S: Within normal limits

What Imaging Should We Order?

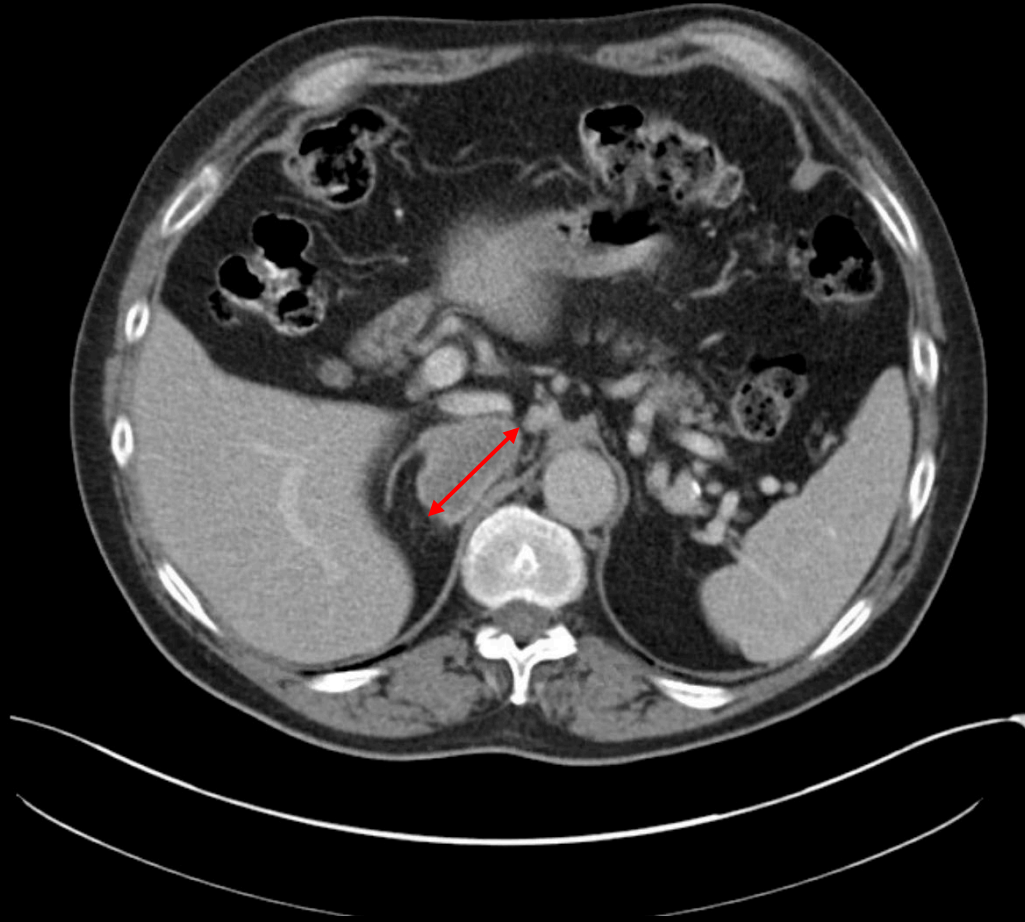
Select the applicable ACR Appropriateness Criteria

<u>Clinical Condition:</u>		Incidentally Discovered Adrenal Mass	
<u>Variant 3:</u>		No history of malignancy; mass >4 cm in diameter. (If not typical for adenoma, myelolipoma, hemorrhage, or simple cyst, consider resection.)	
Radiologic Procedure	Rating	Comments	RRL*
CT abdomen with IV contrast	8	As part of preoperative staging. Alternative to MRI.	⊗⊗⊗
MRI abdomen without and with IV contrast	8	As part of preoperative staging. Alternative to CT.	○
FDG-PET/CT skull base to mid-thigh	5	As part of preoperative staging.	⊗⊗⊗⊗
MIBG	2	Only for suspicion of pheochromocytoma.	⊗⊗⊗
CT abdomen without and with IV contrast	2		⊗⊗⊗⊗
MRI abdomen without IV contrast	1		○
US adrenal gland	1		○
CT abdomen without IV contrast	1		⊗⊗⊗
X-ray abdomen	1		⊗⊗
Iodocholesterol scan	1	This agent may be used to detect functionally active adenomas.	⊗⊗⊗⊗
Biopsy adrenal gland	1		Varies
<u>Rating Scale:</u> 1,2,3 Usually not appropriate; 4,5,6 May be appropriate; 7,8,9 Usually appropriate			*Relative Radiation Level

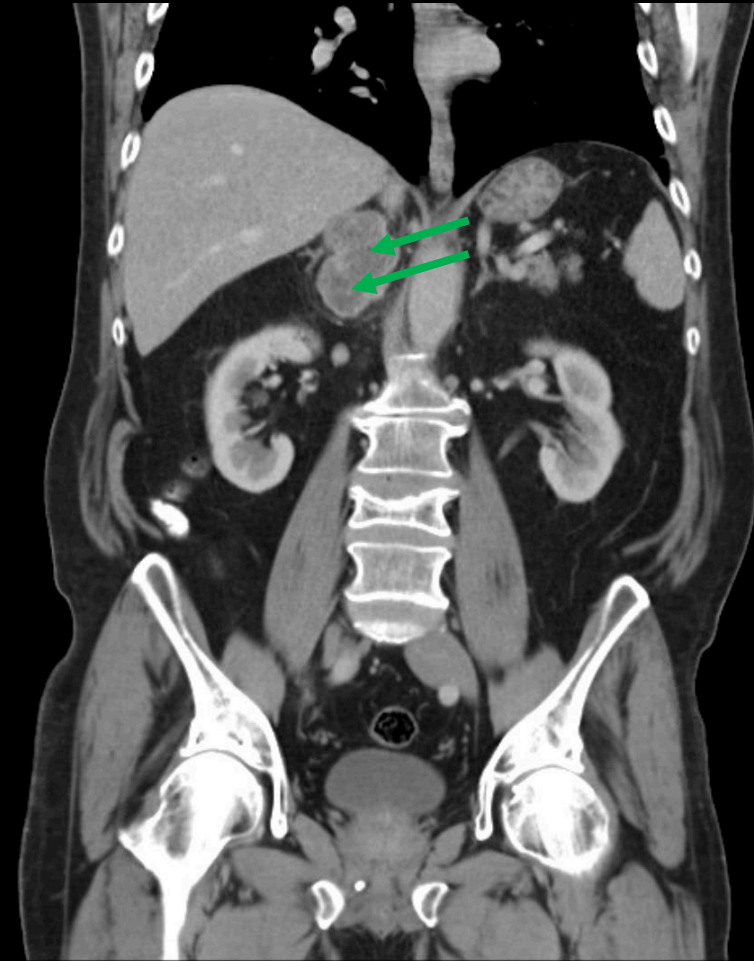
Findings (unlabeled)



Findings (labeled)



Axial CT showing lobulated, rim enhancing right adrenal mass arising from the medial limb measuring 6.3x5x3.2cm (red arrow)



Coronal view showing centrally hypodense areas (green arrows)

DDX based on imaging

- Adrenal adenoma
- Cortical carcinoma
- Metastatic tumor
- Pheochromocytoma
- Leiomyosarcoma
- Lymphoma
- Other adrenal tumor:
 - Ganglioneuroma
 - Neurofibroma
 - Schwannoma

Pertinent Labs

(To rule out Pheochromocytoma)

Urine

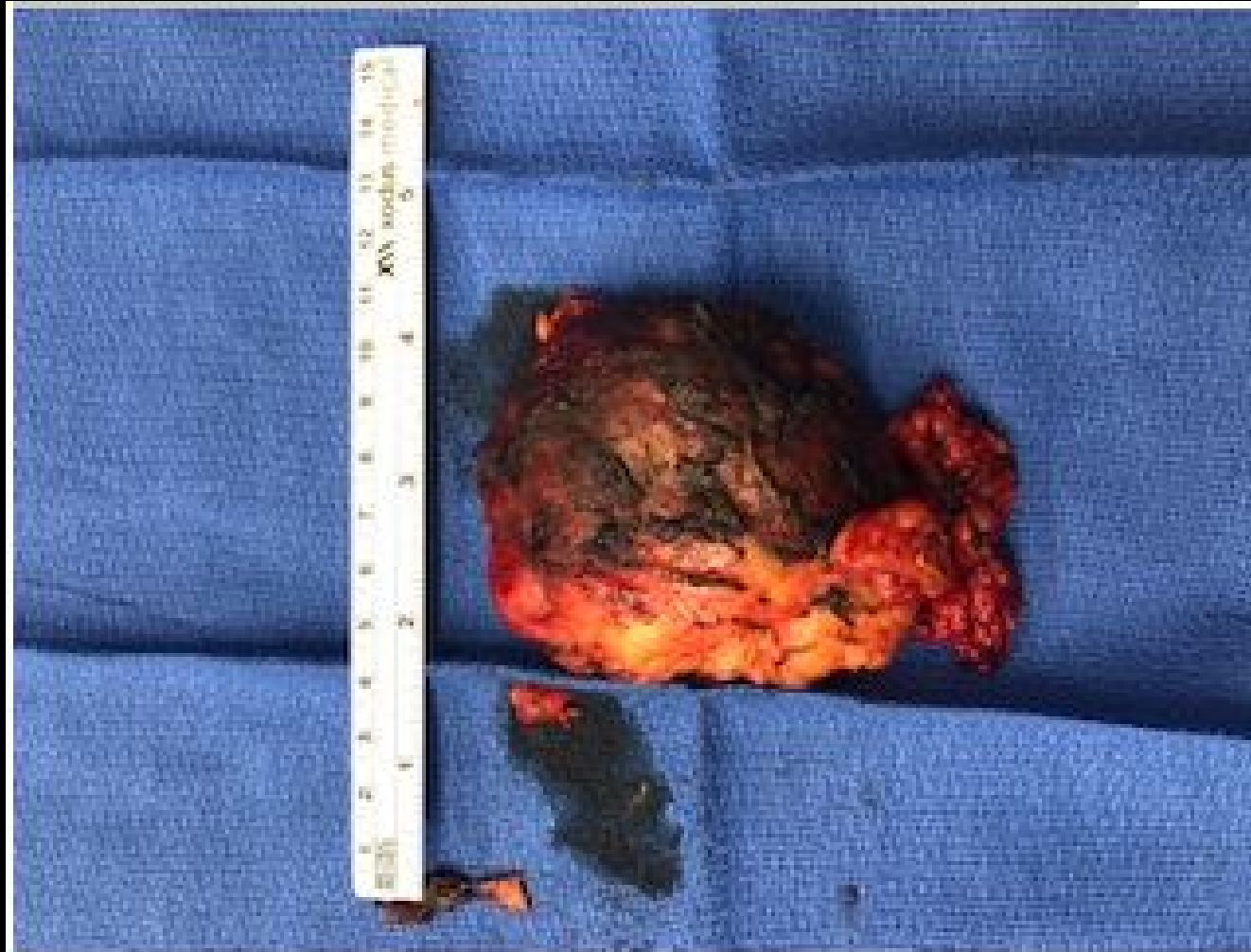Catecholamines, Fractionated	Results	Reference
Norepinephrine	64	15-84 mcg/24h
Epinephrine	8.1	<21 mcg/24h
Dopamine	243	65-400 mcg/24h

Metanephrines, Fractionated	Results	Reference
Metanephrine	245	44-261 mcg/24h
Normetanephrine	514	138-521 mcg/24h
Total Metanephrine	759	233-716 mcg/24h

Plasma

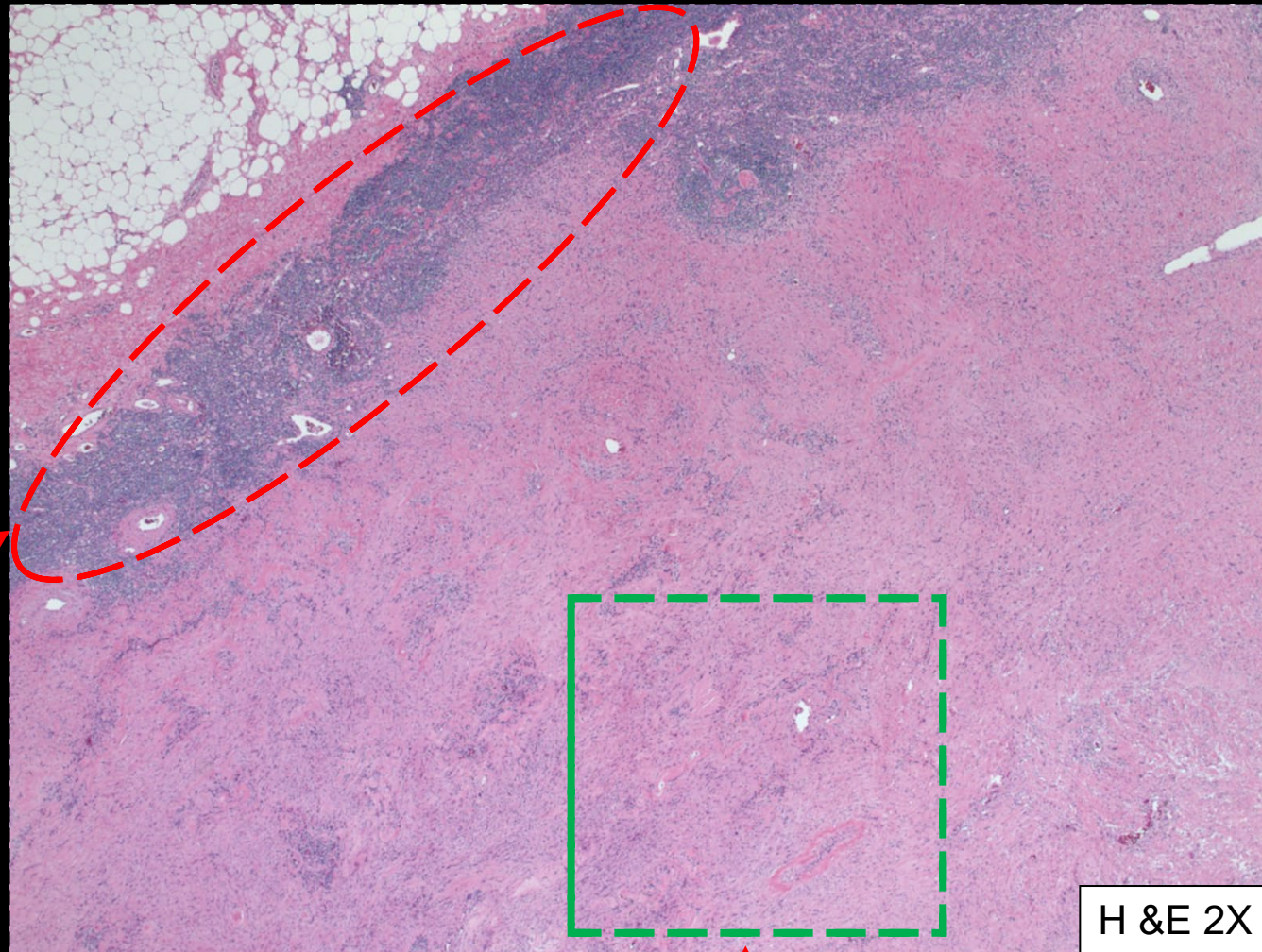
Metanephrines, Fractionated	Results	Reference
Metanephrine, Free	0.31	<0.50 nmol/L
Normetanephrine, Free	0.94	<0.90 nmol/L

Gross Pathology



Right adrenal mass measuring 8.3 x 6.6 x 2.5 cm

Pathology: Histology

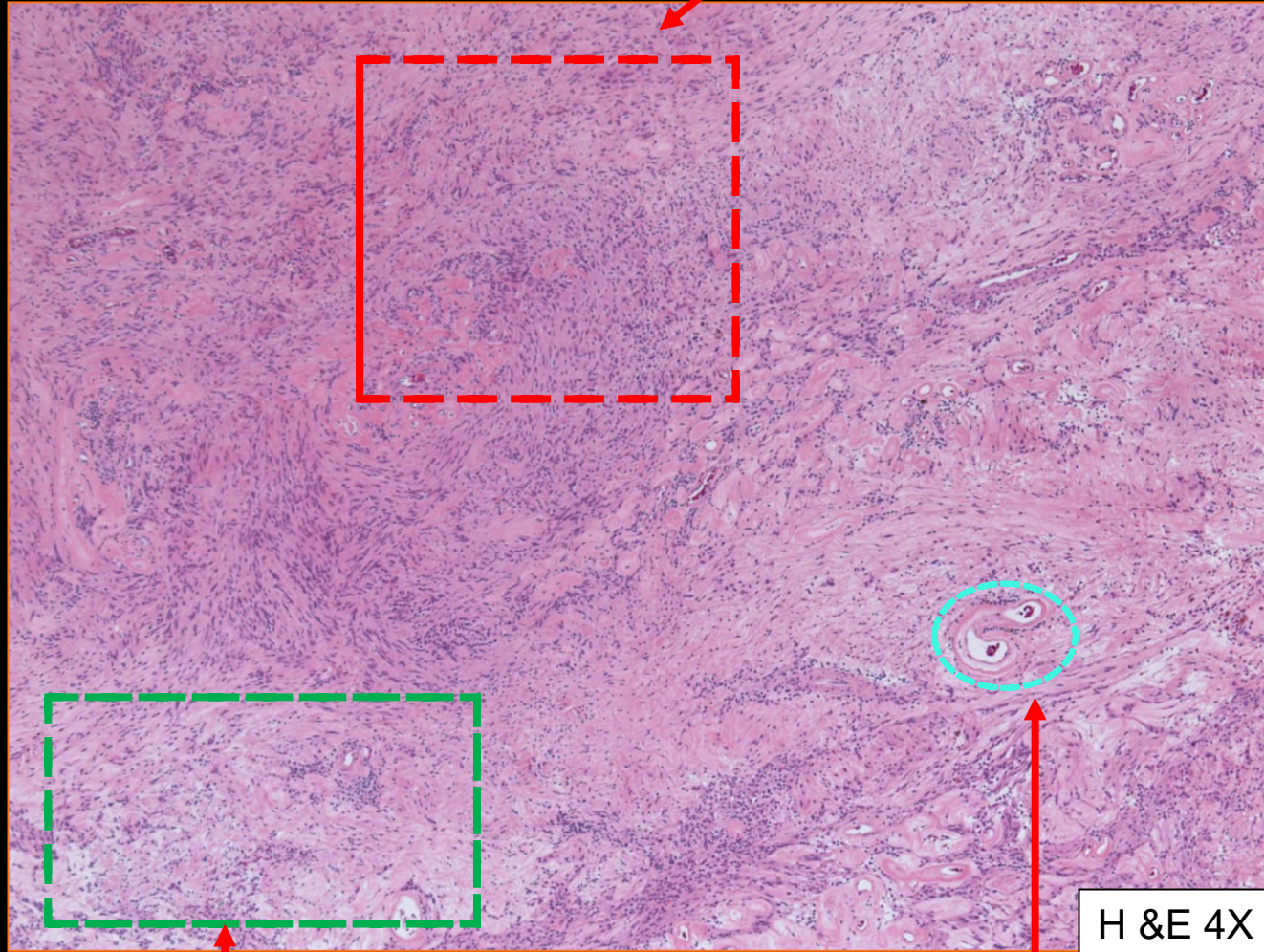


Low power (2x) shows lymphoid aggregate (cuff) at the periphery.

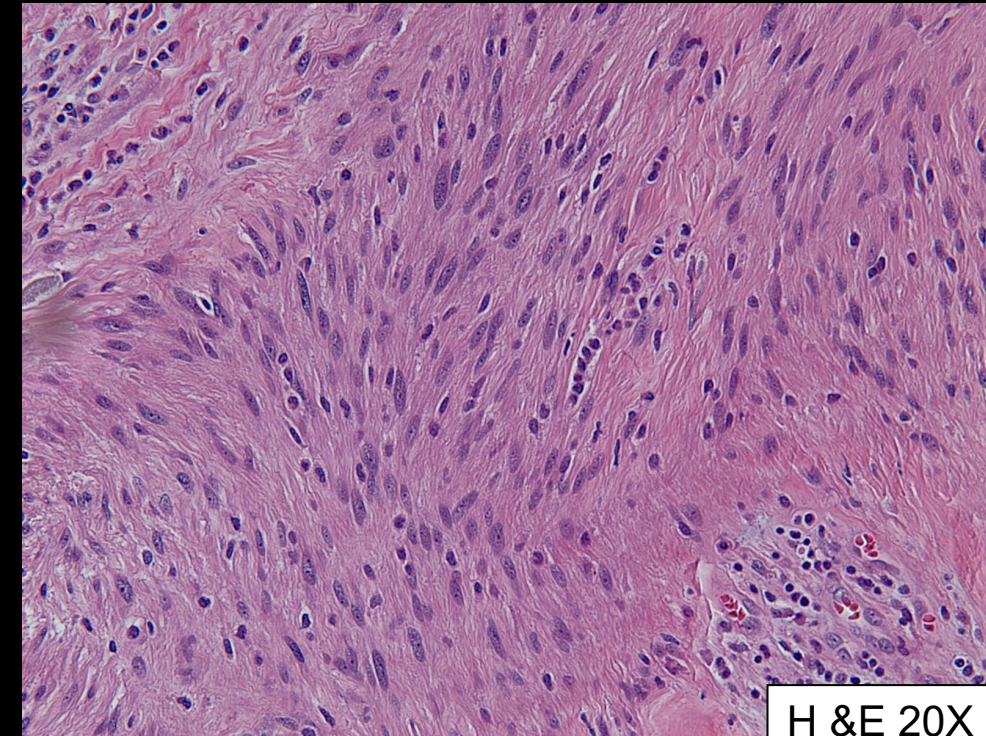
Antoni B areas are myxoid hypocellular

Pathology: Histology

Antoni A area-
compact, hypercellular



Cells are narrow, elongated
and wavy with tapered ends
interspersed with collagen
fibers

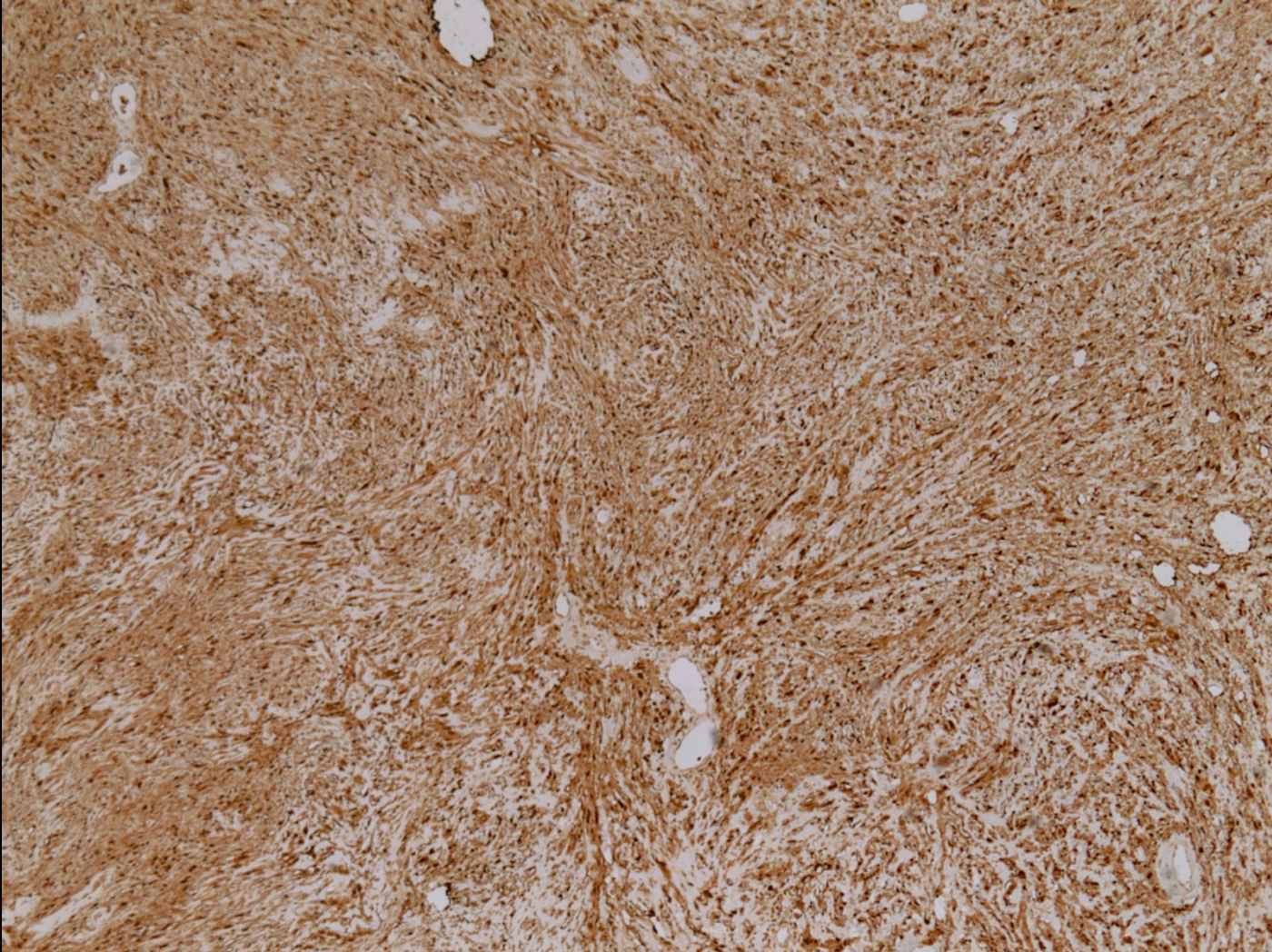


Antoni B area-
myxoid hypocellular

Blood vessels with
thickened hyalinized walls

Pathology: Histology

S100



Main stain for Schwannoma

Final diagnosis

Adrenal Schwannoma

Case discussion

Background

- Adrenal schwannoma is a rare type of adrenal incidentaloma and is found in the medulla
- The adrenal medulla is innervated by the phrenic nerve, the vagus nerve, and the sympathetic trunk
- Adrenal schwannomas are thought to arise from Schwann cells associated with these nerves
- Demonstrate a broad age range, from 14 to 89 years, with a median age of 49
- No clinical or biochemical evidence of endocrine hormonal activity
- The majority of cases are detected incidentally

Case discussion

Management

- Lesions
 - greater than 6 cm should be excised
 - less than 4 cm should not be resected
 - between 4 cm and 6 cm can be either closely observed or resected
- Definitive diagnosis is possible only after histological examination of the operative specimen

Case discussion

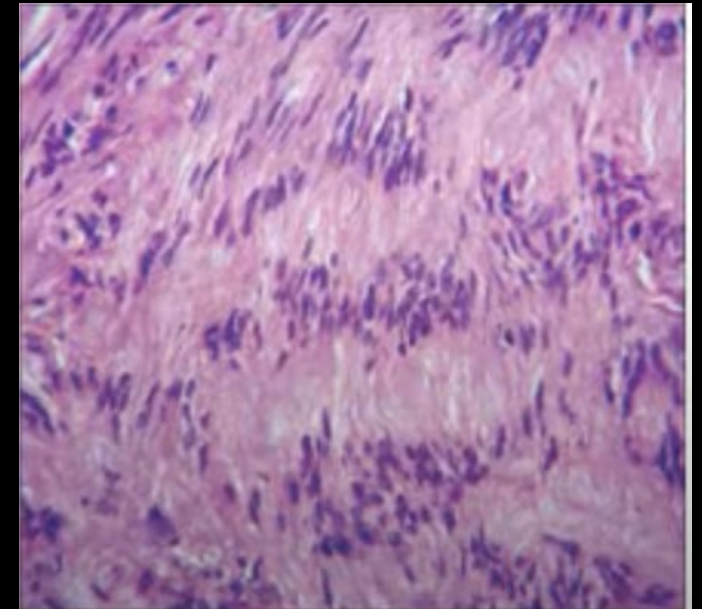
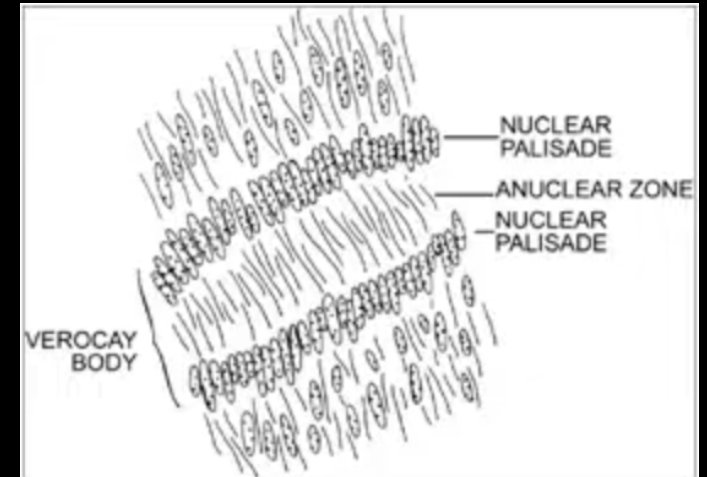
Imaging features

- Abdominal ultrasound (US)
 - hypoechoic mass
- Computed tomography (CT)
 - well-circumscribed, homogenous masses
 - long-standing schwannomas develop
 - cystic degeneration manifesting as heterogeneous masses
 - calcifications
 - variable homogenous or heterogeneous enhancement with contrast
- Magnetic resonance imaging (MRI)
 - T1 weighted images-low signal intensity
 - T2 weighted images-heterogeneous high signal intensity

Case discussion

Pathologic features

- May or may not have a fibrous capsule
- **Antoni A** area
 - compact cellular areas
 - fascicles of spindle cells with indistinct cell borders
 - with cytologically bland nuclei
 - faintly eosinophilic cytoplasm
- **Antoni B** area
 - loosely textured paucicellular areas
- **Verocay bodies**
 - nuclear-free zones in between regions of nuclear palisading
- **Blood vessels** thick-walled, hyalinized



References:

ACR Appropriateness Criteria: Incidentally discovered adrenal mass. American College of Radiology.
<https://acsearch.acr.org/docs/69366/Narrative/>. Updated 2012.

Abdellatif E. Schwannoma. PathologyOutlines.com website. <http://www.pathologyoutlines.com/topic/softtissueschwannoma.html>.

Bell, D. Adrenal lesions (differential). Radiopaedia.com website. <https://radiopaedia.org/articles/adrenal-lesions-differential?lang=us>

Yaseen Mohiuddin, Mary G. F. Gilliland; Adrenal Schwannoma: A Rare Type of Adrenal Incidentaloma. *Arch Pathol Lab Med* 1 July 2013; 137 (7): 1009–1014. doi: <https://doi.org/10.5858/arpa.2012-0291-RS>

<https://images.app.goo.gl/Kz7QxhZP9zZSjFKZA>