

AMSER Rad Path Case of the Month:

59-year-old male with headaches and left arm numbness

Iger Ostreni, OMS-IV, Touro College of Osteopathic Medicine

Matthew Hartman, MD, Allegheny Health Network

Jonathan Pace, MD, Allegheny Health Network

Kymerly Gyure, MD, Allegheny Health Network

Alfonzo Halfin Guerrero, MD, Allegheny Health Network

Lisa Andersen, MD, Allegheny Health Network

Matthew Kulzer, MD, Allegheny Health Network



Patient Presentation

- **HPI:** 59 y/o M evaluated in the ED for headaches, left arm numbness and occasional “electric bolt” sensation in right eye for 3 months.
- **PMHx:** Hypertension, hyperlipidemia, gastroesophageal reflux disease, depression, Lasik surgery
- **PSHx:** 50 pack year smoking history, occasional alcohol use.
- **Allergies:** none
- **Family Hx:** Mother has diabetes. Father with no known problems.
- **ROS:** Left hand numbness and headaches.

Patient Presentation

- **Vitals:** HR 76 bpm, BP: 133/82, respiratory rate: 20, Temp: 97.7, SpO2: 97%
- **PE:** Left pupil 4 mm reactive, right pupil 3 mm reactive. Motor strength 4/5 in left upper extremity, possible left sided pronator drift, however, may be due to diffuse LUE weakness. Decreased sensation to left hand and patchy numbness in left forearm.
- **Labs:** Unremarkable.

What Imaging Should We Order?

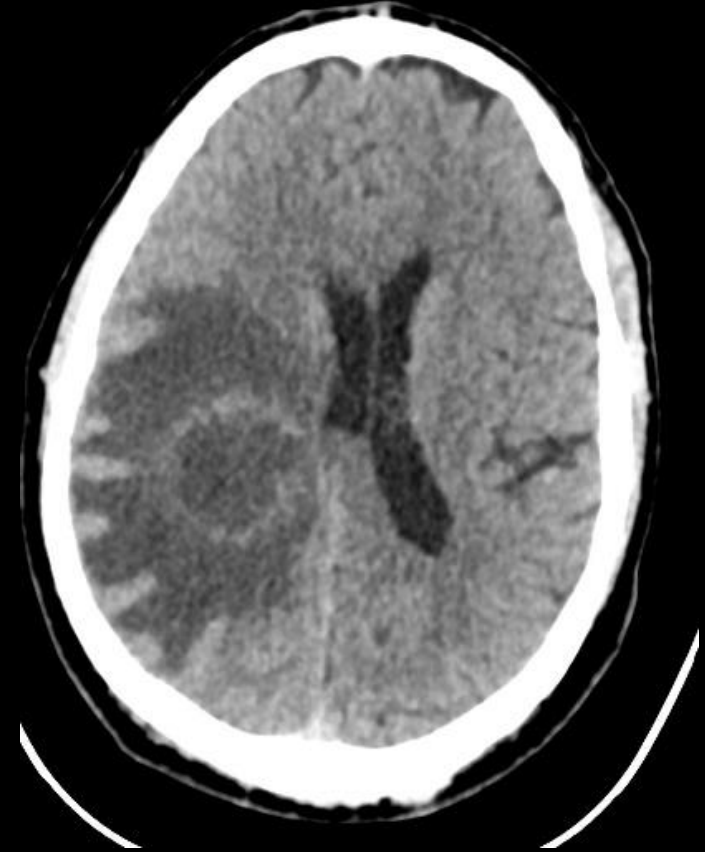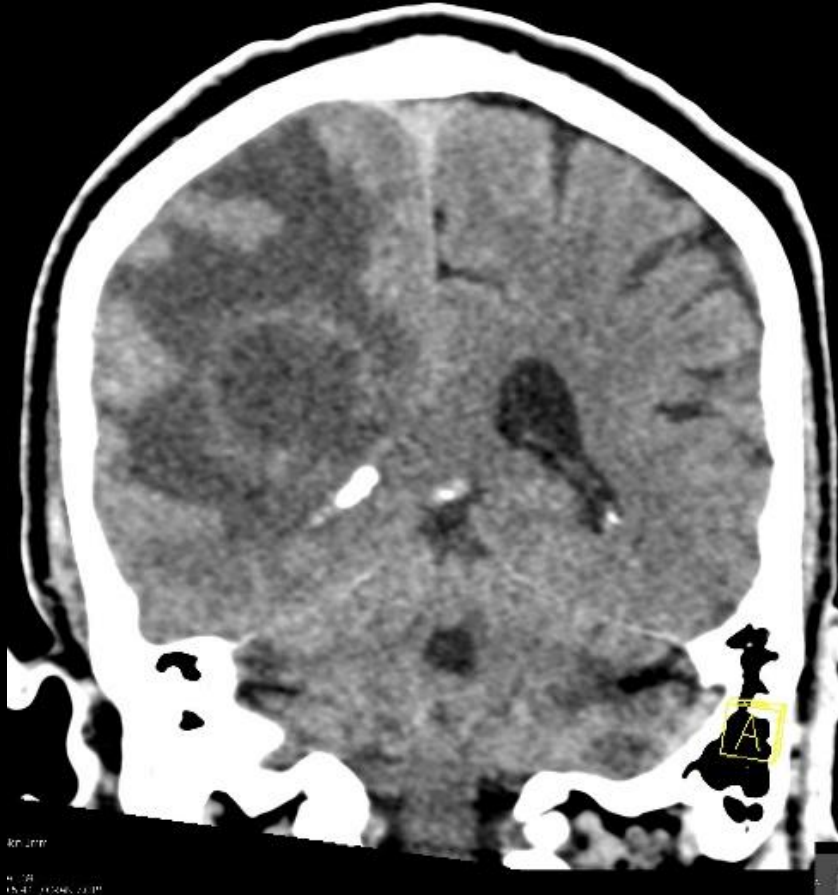
Select the applicable ACR Appropriateness Criteria

Variant 3: New or progressively worsening headache with one or more of the following 'red flags': subacute head trauma, related activity or event (sexual activity, exertion, position), neurological deficit, known or suspected cancer, immunosuppressed or immunocompromised state, currently pregnant, or 50 years of age or older. Initial imaging.

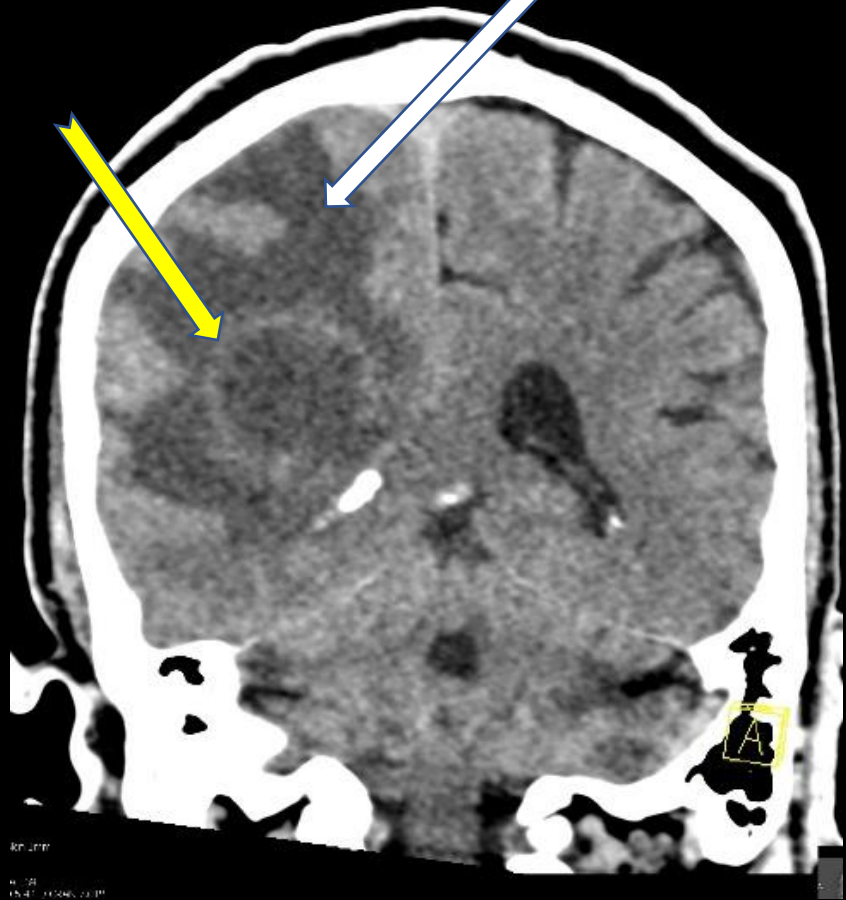
Procedure	Appropriateness Category	Relative Radiation Level
CT head without IV contrast	Usually Appropriate	⊕⊕⊕
MRI head without and with IV contrast	Usually Appropriate	○
MRI head without IV contrast	Usually Appropriate	○
CT head with IV contrast	Usually Not Appropriate	⊕⊕⊕
CTA head with IV contrast	Usually Not Appropriate	⊕⊕⊕
MRA head without IV contrast	Usually Not Appropriate	○
CT head without and with IV contrast	Usually Not Appropriate	⊕⊕⊕
Arteriography cervicocerebral	Usually Not Appropriate	⊕⊕⊕
MRA head without and with IV contrast	Usually Not Appropriate	○

This imaging modality was ordered by the ER physician

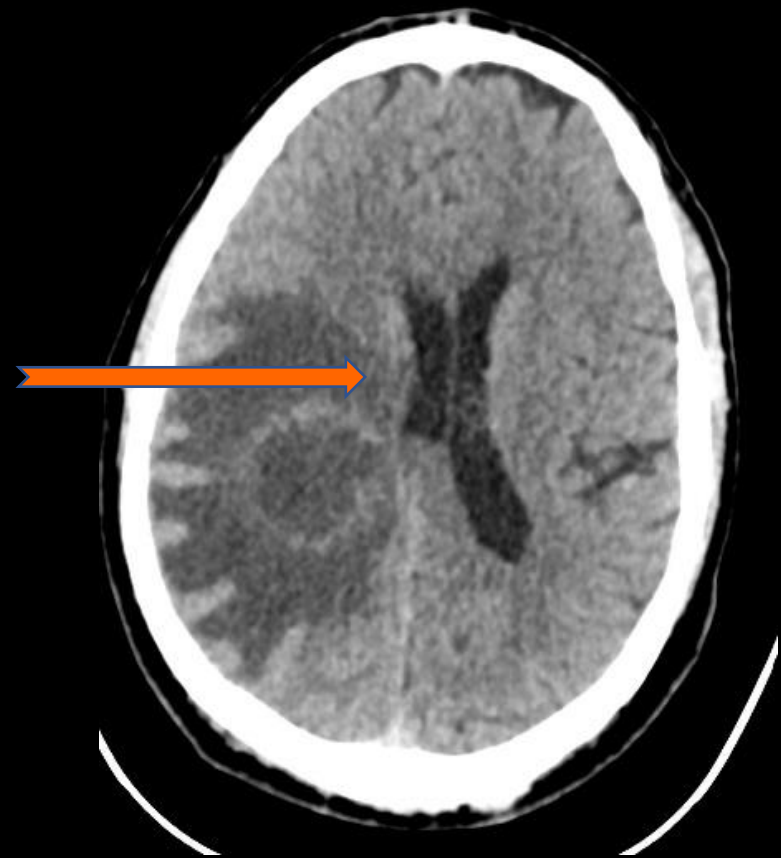Findings (unlabeled)



Findings (labeled)



There is a right frontoparietal/periatrial mass with peripheral irregular hyperdensity (yellow arrow) and internal hypodensity with surrounding vasogenic edema (white arrow) and local mass effect.



There is leftward shift (orange arrow) of approximately 8 mm.

What additional Imaging Should We Order to better Characterize the Mass?

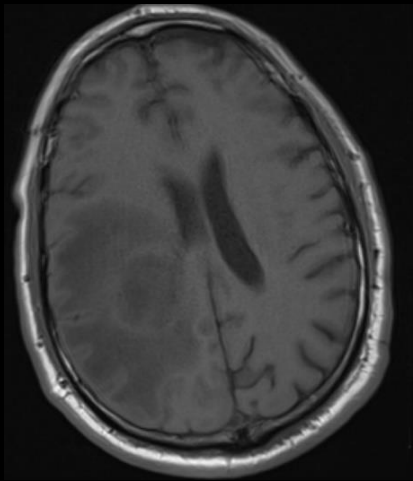
Select the applicable ACR Appropriateness Criteria

Variant 3: New or progressively worsening headache with one or more of the following 'red flags': subacute head trauma, related activity or event (sexual activity, exertion, position), neurological deficit, known or suspected cancer, immunosuppressed or immunocompromised state, currently pregnant, or 50 years of age or older. Initial imaging.

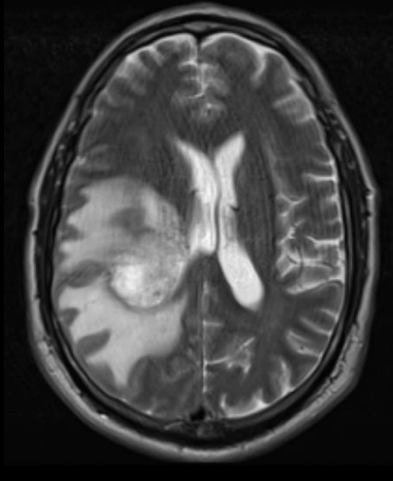
Procedure	Appropriateness Category	Relative Radiation Level
CT head without IV contrast	Usually Appropriate	⊕⊕⊕
MRI head without and with IV contrast	Usually Appropriate	○
MRI head without IV contrast	Usually Appropriate	○
CT head with IV contrast	Usually Not Appropriate	⊕⊕⊕
CTA head with IV contrast	Usually Not Appropriate	⊕⊕⊕
MRA head without IV contrast	Usually Not Appropriate	○
CT head without and with IV contrast	Usually Not Appropriate	⊕⊕⊕
Arteriography cervicocerebral	Usually Not Appropriate	⊕⊕⊕
MRA head without and with IV contrast	Usually Not Appropriate	○

This imaging modality was ordered by the ED physician

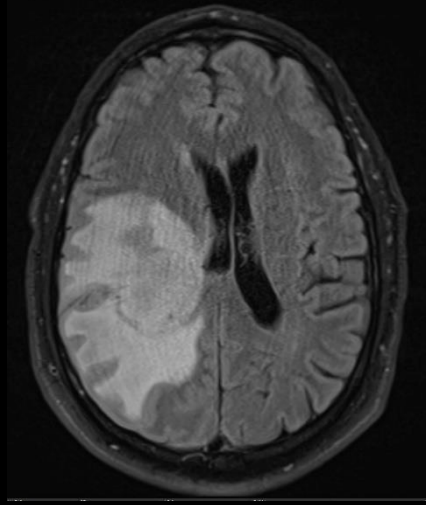
Findings (unlabeled)



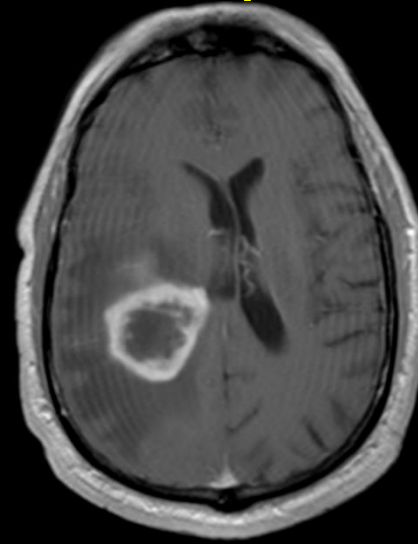
T1



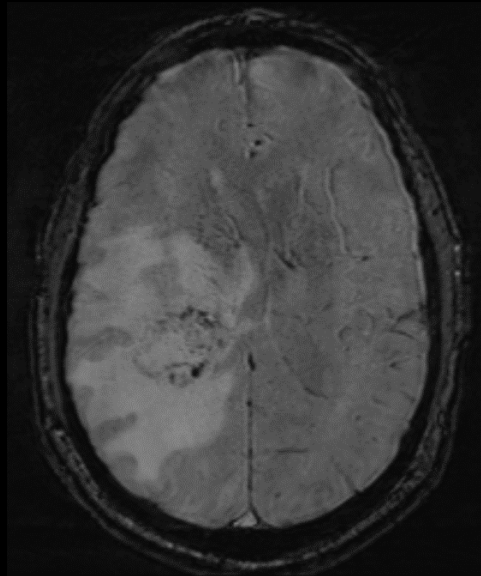
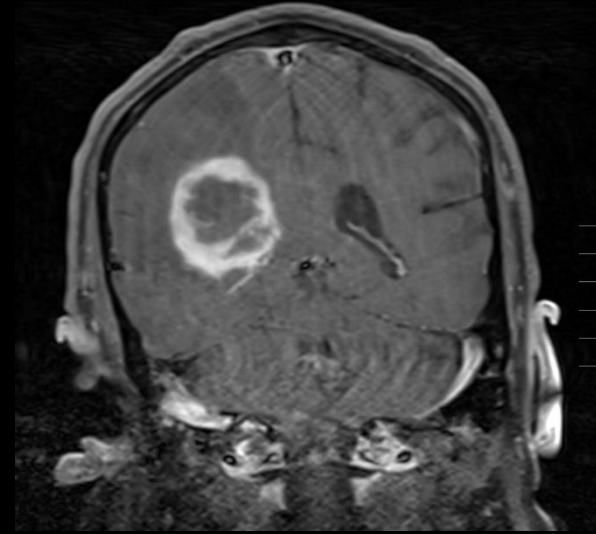
T2



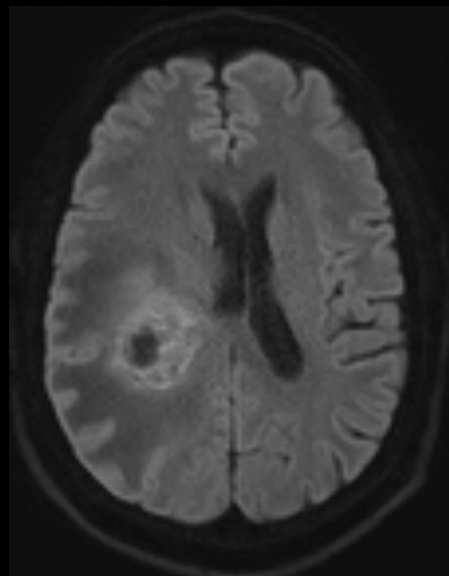
FLAIR



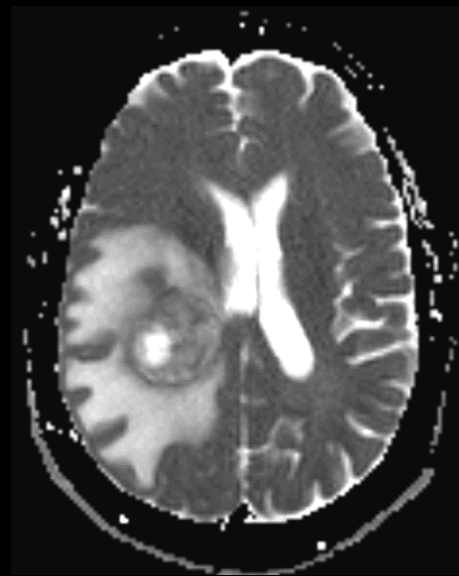
T1 + Contrast



SWI

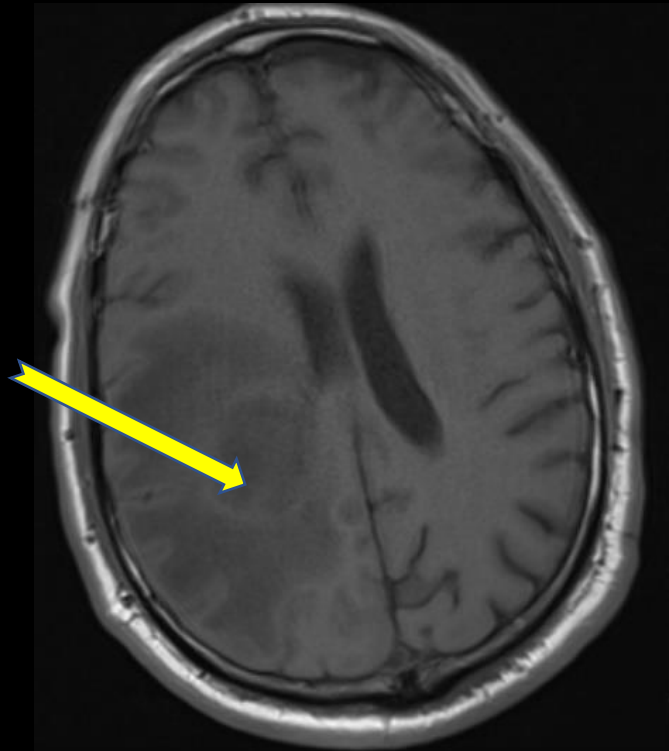


DWI

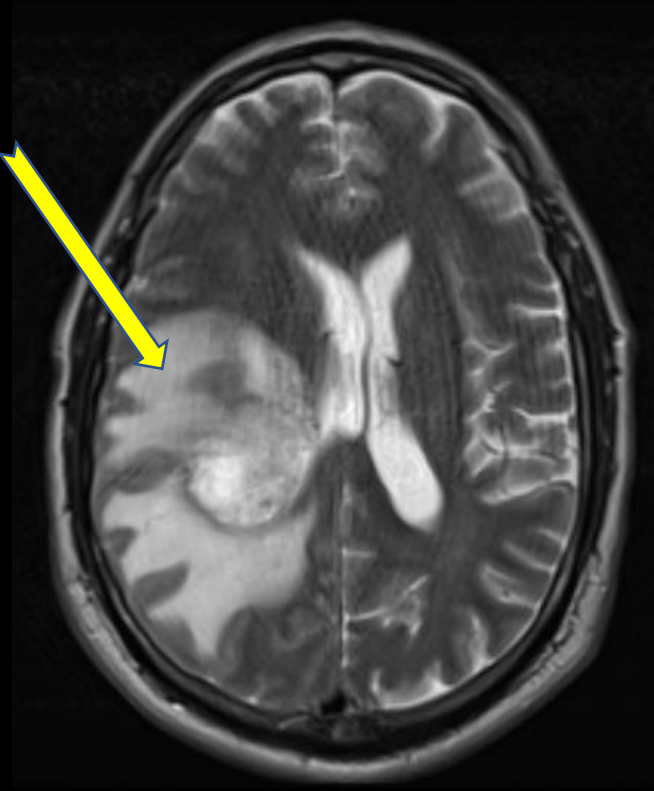


ADC

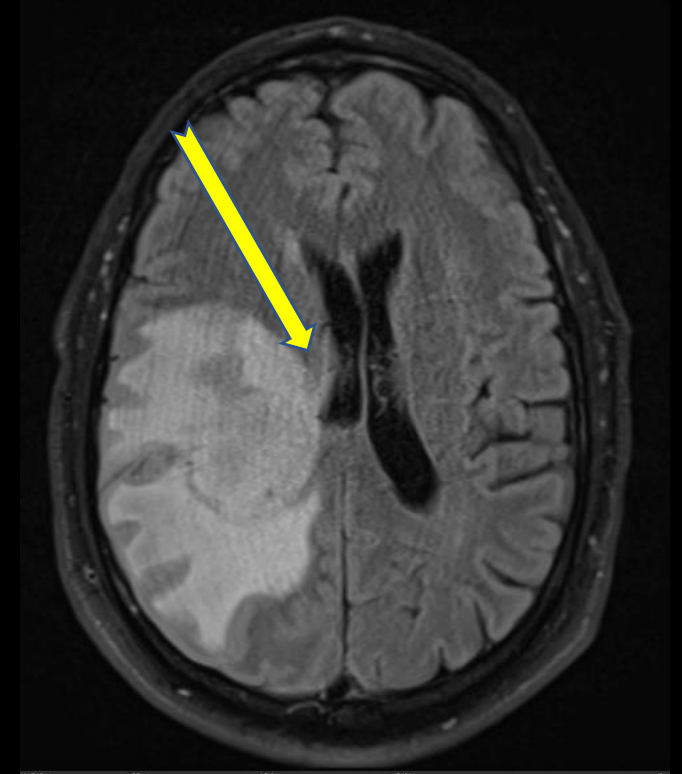
Findings (labeled)



T1



T2



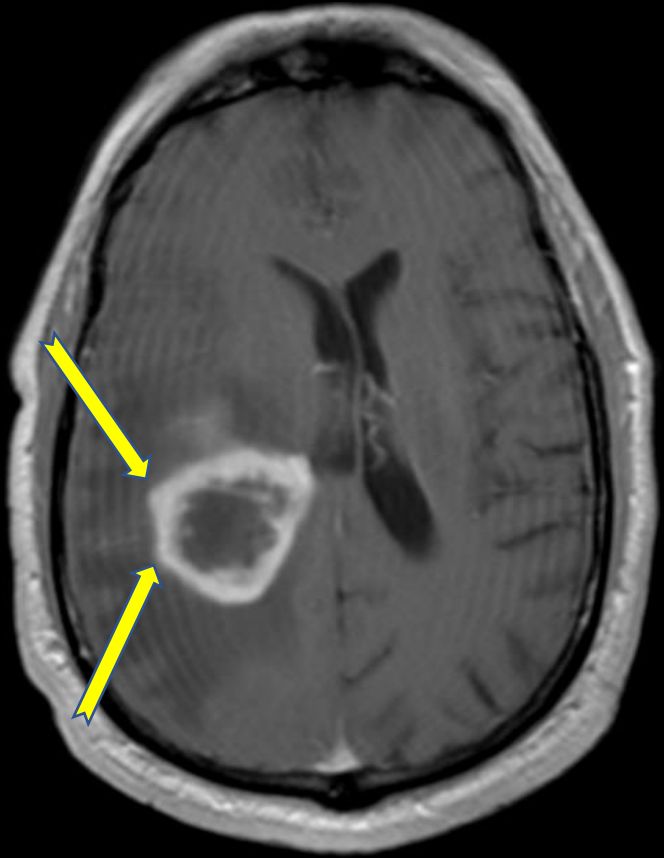
FLAIR

On T1 the mass is predominantly hypointense with central heterogeneous signal.

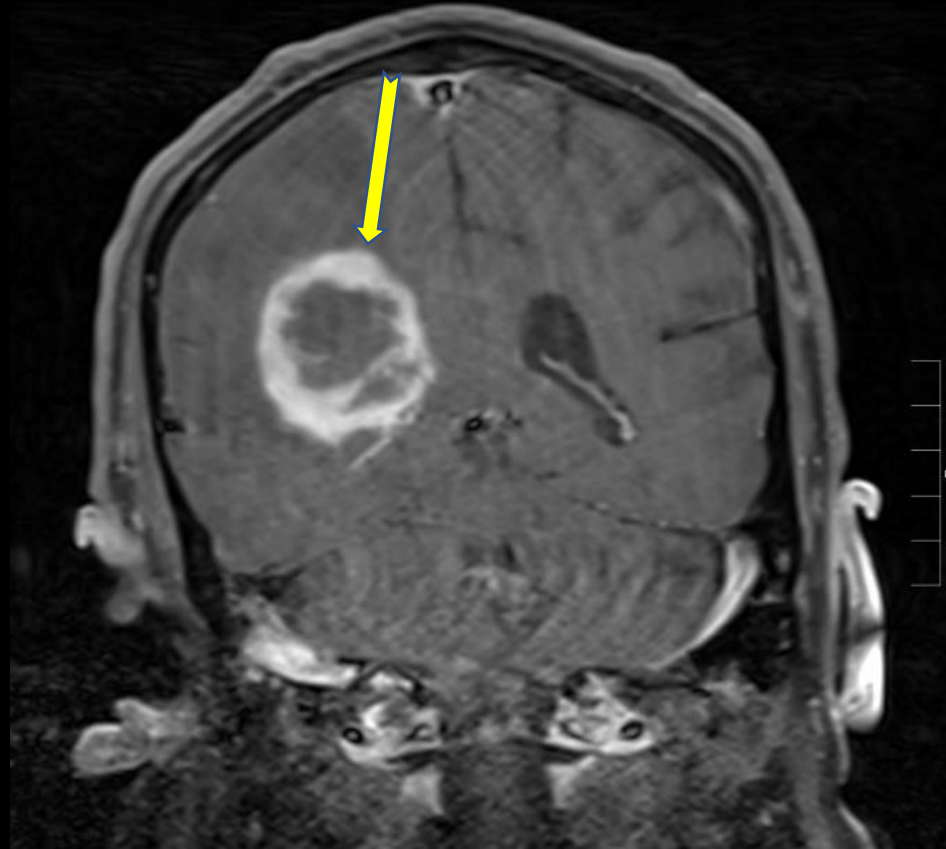
The mass is predominantly T2 hyperintense. There is surrounding abnormal T2 prolongation which could reflect vasogenic edema, however, in high grade CNS neoplasms, it could also represent a component of infiltrative non-enhancing tumor. (Both are likely present).

There is mass effect and partial effacement of right lateral ventricle.

Findings (labeled)



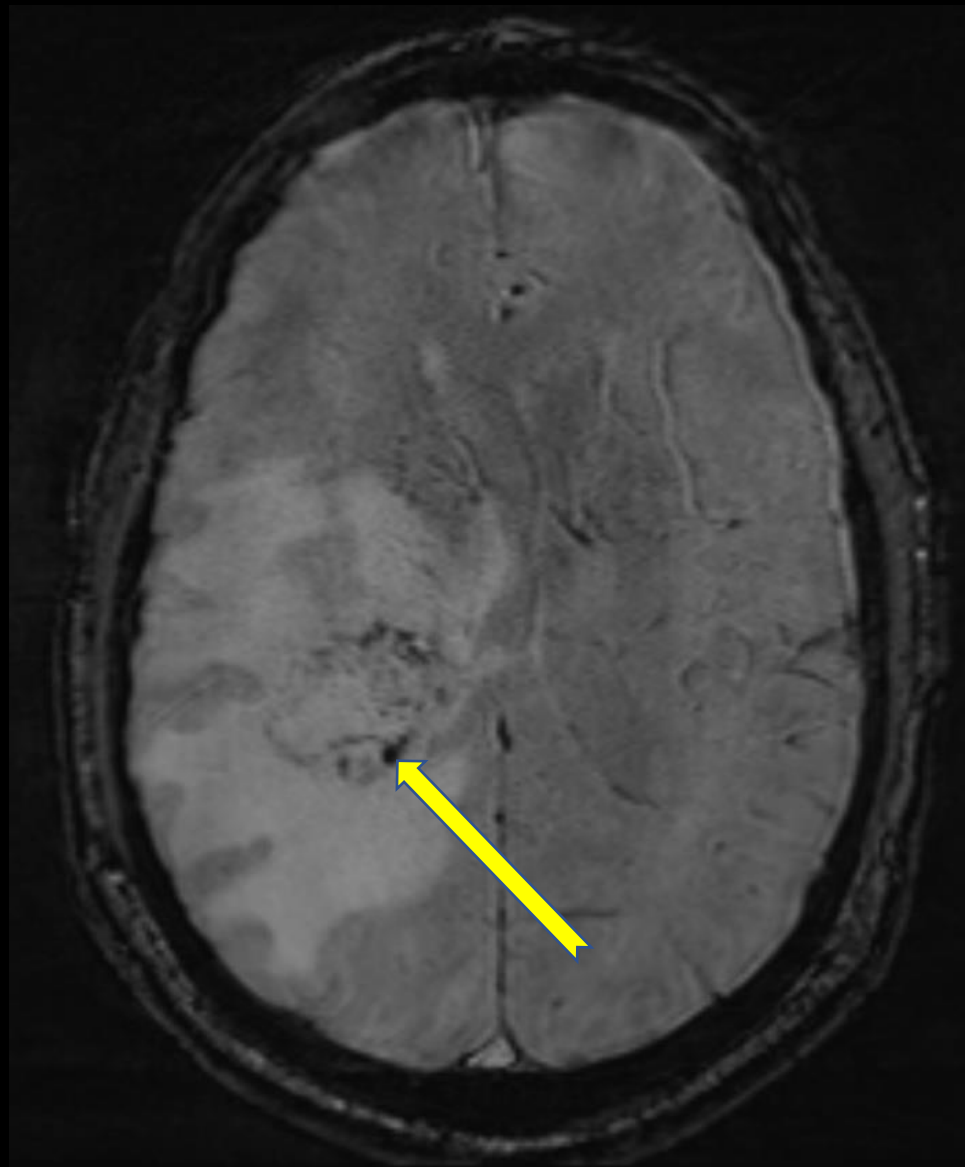
T1 + Contrast



T1 with Gadolinium contrast shows a peripheral irregular enhancing intraaxial mass with nodular components.

The nonenhancing internal components central to the mass likely represent necrosis.

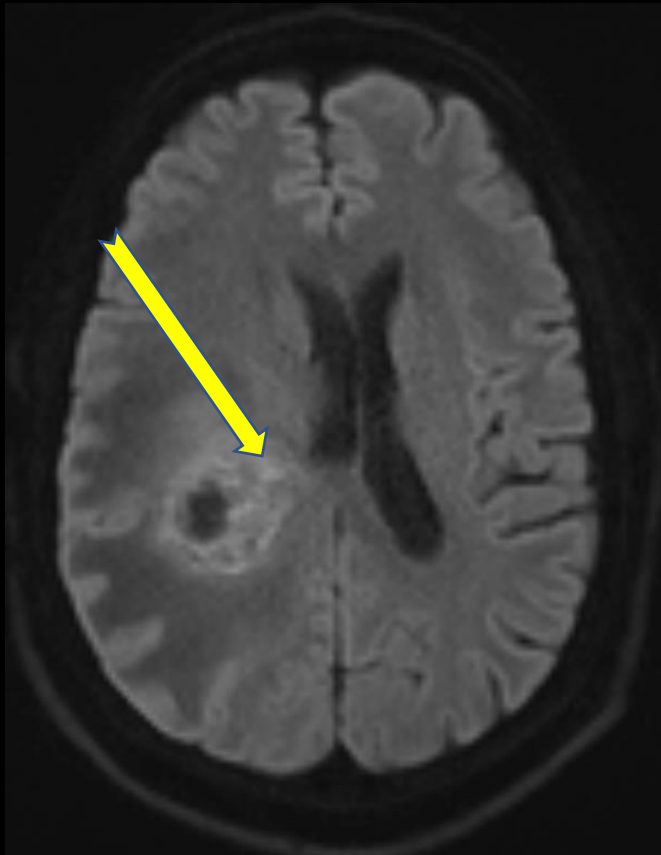
Findings (labeled)



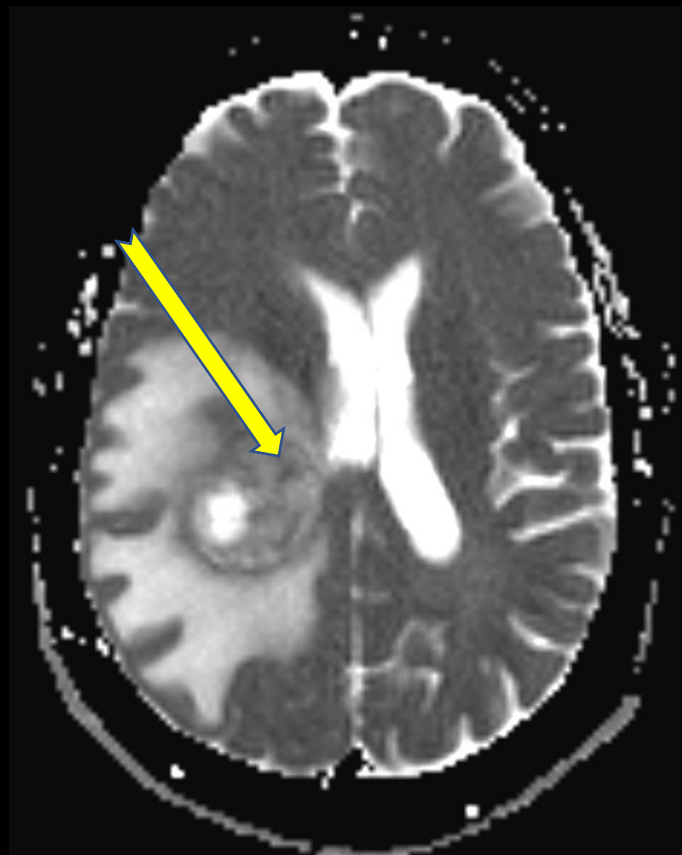
SWI

Portions of the mass at the enhancing component also demonstrate blooming on susceptibility weighted imaging, suspicious for foci of intracranial hemorrhage.

Findings (labeled)



DWI



ADC

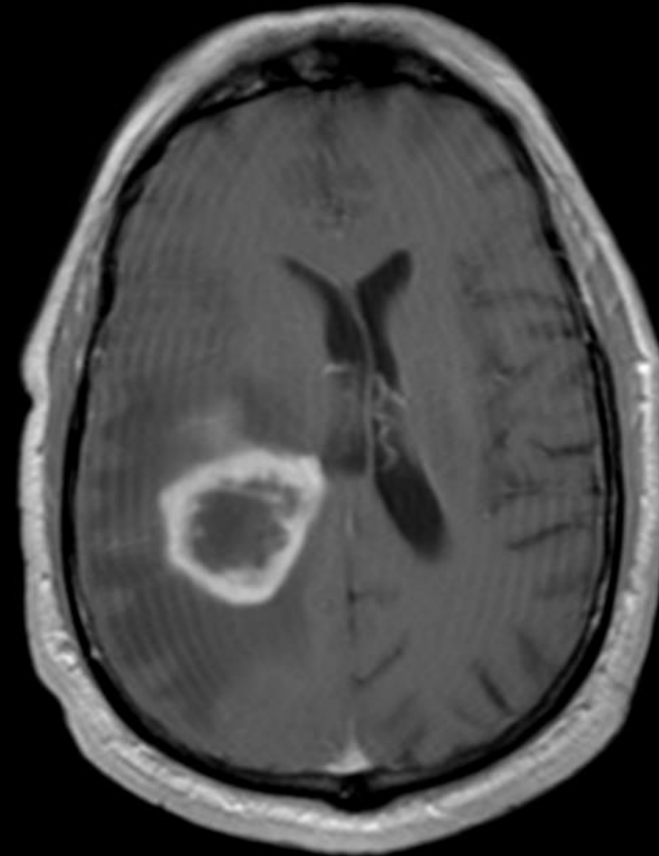
Comparing DWI to ADC shows that there is diffusion restriction associated with the enhancing component, suspicious for hypercellularity.

Differential Diagnosis

Differential for Ring Enhancing Mass includes:

- M** •Metastasis
- A** •Abscess
- G** •Glioblastoma
- I** •Infarction (subacute)
- C** •Contusion
- A** •AIDS* related (toxoplasmosis)
- L** •Lymphoma (immunosuppressed)

- D** •Demyelination
- R** •Radiation Necrosis



T1 + Contrast

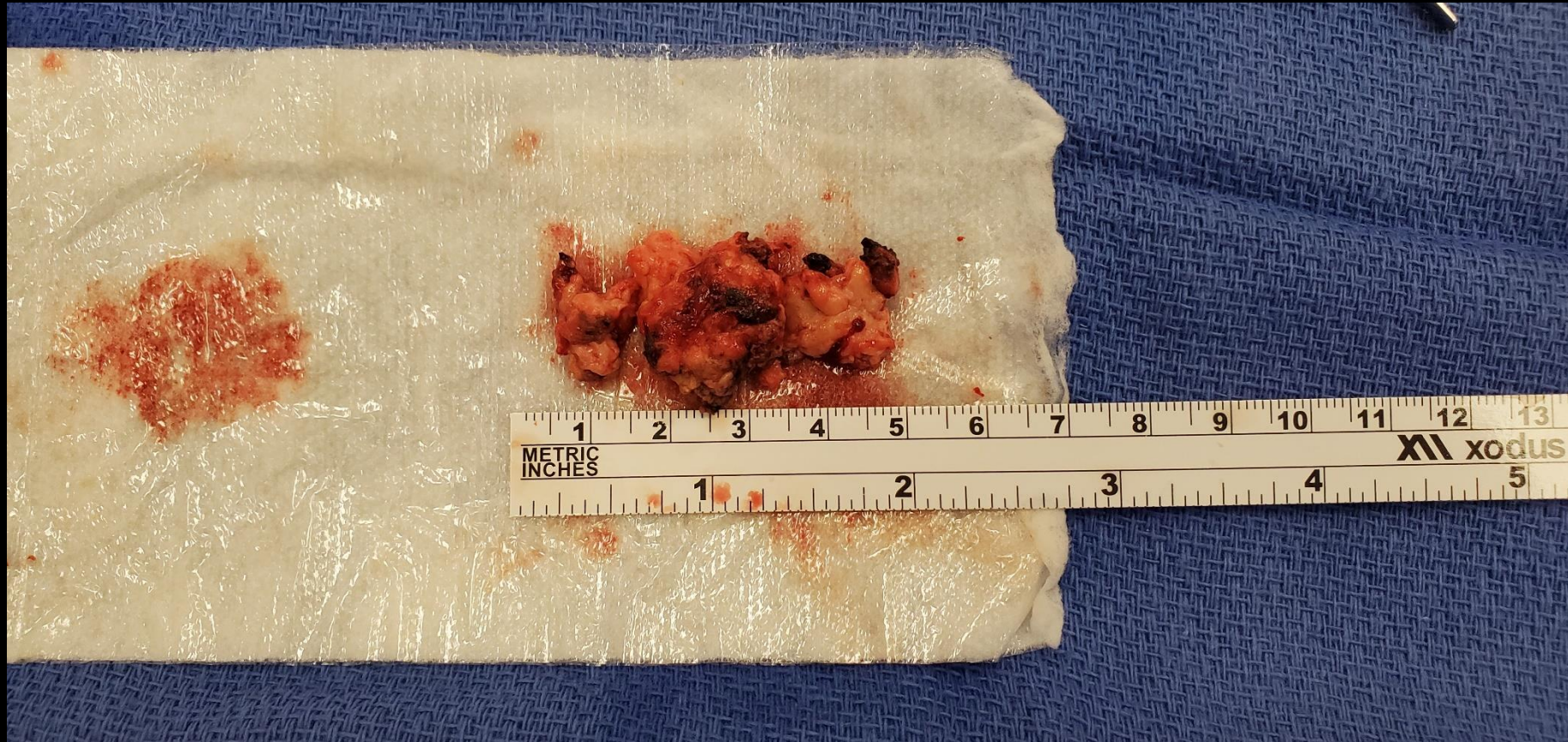* Not all AIDS related diseases enhance (i.e HIV encephalopathy)

Differential Diagnosis

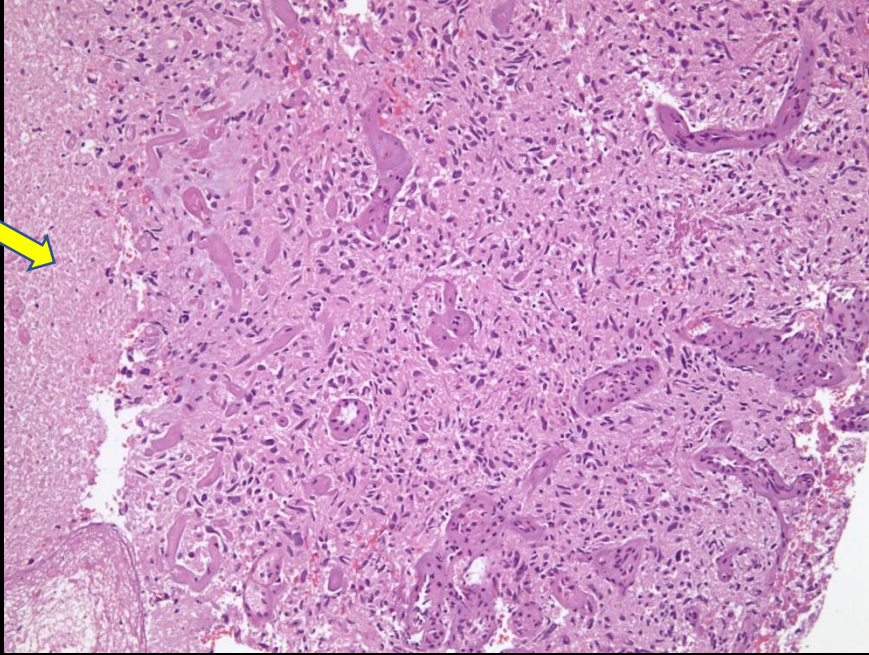
- Metastasis can vary widely in appearance, however, in this case, the large size of this solitary lesion leads more towards a primary tumor.
- The patient does not have a history of AIDS to suggest toxoplasmosis, lymphoma or previous radiation history so they are excluded from the differential.
- The best way to distinguish glioblastoma from abscess is through diffusion restriction. Although both entities ring enhance, the abscess has central diffusion restriction without diffusion restriction at the enhancing components, whereas glioblastoma has diffusion restriction peripherally and usually at its enhancing components.
- Another way to distinguish glioblastoma from brain abscess is with the dual rim sign. 75% of brain abscesses have the dual rim sign (absent on this case) on T2-weighted images and SWI. (Dual rim sign refers to concentric rims around an abscess cavity with the outer hypointense and the inner hyperintense on both T2 and susceptibility weighted imaging).
- Although contusions can occur anywhere, they are most common in the anterior cranial fossa floor, temporal pole, and appear in a coup and contrecoup pattern which was not the location of the mass in this case.

Final Dx:

Grade IV Glioblastoma

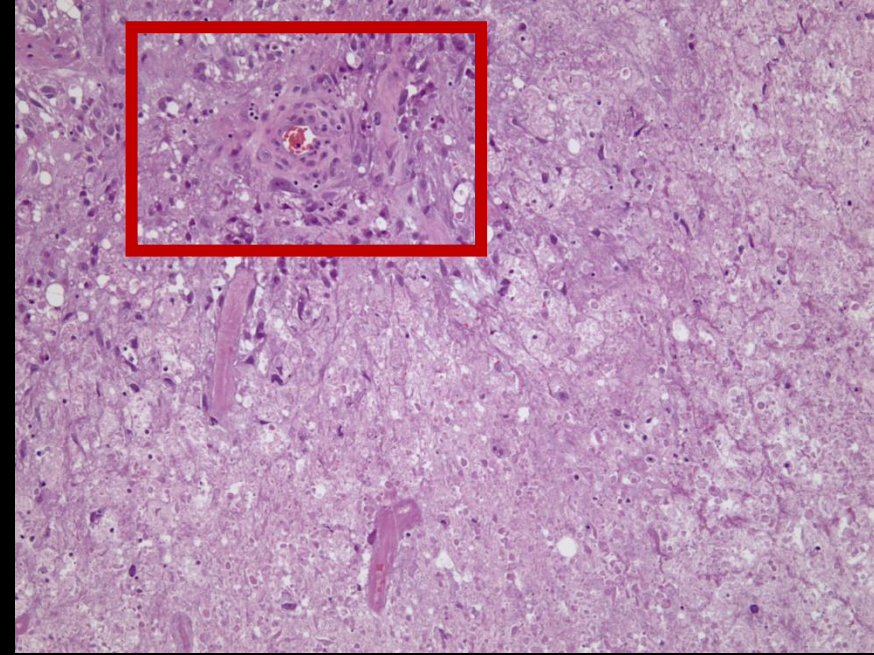


Case Discussion - Grading



Necrosis bordering on tumor cells (arrow).

High degree of nuclear pleomorphism and markedly increased nuclear:cytoplasmic ratio in many tumor cells.



Transition from densely cellular tissue (upper left) to necrosis (lower right) with microvascular proliferation (red box).

Histologic Grading	
GRADE II	Cytologic atypia (variation in nuclear shape and size + hyperchromasia)
GRADE III	Anaplasia and increased mitotic activity (increased cellularity)
GRADE IV	Microvascular proliferation and necrosis



Case Discussion

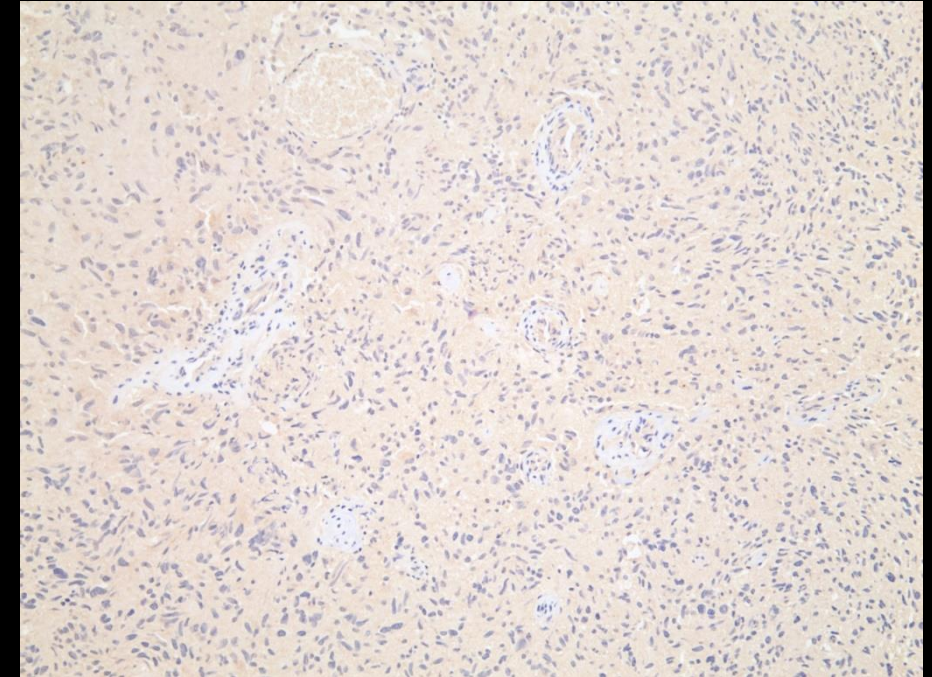
- Glioblastoma is the most common and aggressive primary brain tumor in adults carrying the worst prognosis and accounts for 47.7% of all cases.
- Incidence is 3.21 per 100,000. More common in men compared to women.
- Primary glioblastoma usually occurs in older patients with a mean age of 62 and carries a worse prognosis from secondary glioblastomas that arise from lower grade astrocytoma or oligodendoglioma in younger patients (mean age 45).
- Almost always fatal with a 1 year survival of 40% after diagnosis and 17% in second year.

Case Discussion – Radiographic features

- CT: irregular margins that are iso- to slightly hyperattenuating indicating high cellularity with a hypodense center representing necrosis. Mass surrounded by vasogenic edema.
- T1 MRI: Hypo to isointense mass in the white matter. Central heterogenous signal can indicate necrosis or intratumoral hemorrhage.
- T1 with Contrast: usually peripheral and irregular enhancement with nodular components surrounding a central area of necrosis.
- T2/FLAIR: hyperintense mass with surrounding vasogenic edema/infiltrative non-enhancing tumor. Vasogenic edema and infiltrative non-enhancing tumor can be difficult to clearly distinguish on imaging. Usually both are present.
- DWI/ADC: Diffusion restriction is often seen in the enhancing component which can help distinguish glioblastoma from brain abscess.
- SWI: susceptibility artifact on T2 from blood products or calcification. Dual rim sign is absent (can help distinguish from brain abscess).

Case Discussion – Treatment/Prognosis

- Recommended course is maximal surgical resection followed by chemotherapy.
- *MGMT-unmethylated tumors <70 years old: poor prognosis and response to standard therapies. Less benefit from Temozolomide. Encouraged to participate in clinical trials.
- MGMT status unknown <70 years old: Temozolomide + radiation therapy.
- Older adults with comorbidities: Single modality therapy is recommended.
- Isocitrate dehydrogenase (*IDH1/2*) mutations confer improved prognosis and eligibility for clinical trials.
- * This case involved a MGMT unmethylated tumor. Patient might be enrolled in a clinical trial (NRG BN007) which compares Ipilimumab and Nivolumab vs Temozolomide in patients with MGMT unmethylated glioblastoma.



Immunohistochemical stain for mutant (R132H) form of isocitrate dehydrogenase 1 (IDH1).

This specimen is negative, i.e. IDH wild type.

Case Discussion – Potential therapeutic targets

Important Molecular Alterations in Glioblastoma	
IDH mutation	Prognostic value, potential therapeutic target
MGMT methylation status	Prognostic value, predictive value for response to temozolomide
EGFR mutation	Diagnostic maker for glioblastoma, potential therapeutic target
TERT promoter mutation	Diagnostic maker for glioblastoma
Gain for 7p and loss of 10q	Diagnostic maker for glioblastoma
H3F3A	Diagnostic marker for a subset of gliomas (H3 K27M-mutant and H3 G34 mutant), therapeutic target
FGFR fusion	Therapeutic target
NTRK fusion	Therapeutic target

References:

- American College of Radiology ACR Appropriateness Criteria: Headache
- D.G. Trembath, Chapter 26 - Molecular Testing for Glioblastoma, Editor(s): William B. Coleman, Gregory J. Tsongalis, Diagnostic Molecular Pathology, Academic Press, 2017, Pages 339-347, ISBN 9780128008867, <https://www.sciencedirect.com/science/article/pii/B9780128008867000261>.
<https://www.sciencedirect.com/topics/medicine-and-dentistry/isocitrate-dehydrogenase>
- Glioblastoma multiforme. AANS. (n.d.). Retrieved November 4, 2021, from <https://www.aans.org/en/Patients/Neurosurgical-Conditions-and-Treatments/Glioblastoma-Multiforme>.
- Gaillard, F. (n.d.). Glioblastoma, IDH-wildtype: Radiology reference article. Radiopaedia Blog RSS. Retrieved November 8, 2021, from <https://radiopaedia.org/articles/glioblastoma-idh-wildtype?lang=us>.
- Urbańska K, Sokołowska J, Szmidt M, Sysa P. Glioblastoma multiforme - an overview. Contemp Oncol (Pozn). 2014;18(5):307-12.
- Gaillard, F. (n.d.). *Cerebral hemorrhagic contusion: Radiology reference article*. Radiopaedia Blog RSS. Retrieved November 11, 2021, from <https://radiopaedia.org/articles/cerebral-haemorrhagic-contusion?lang=us>.
- Toh CH, Wei KC, Chang CN, Hsu PW, Wong HF, Ng SH, Castillo M, Lin CP. Differentiation of pyogenic brain abscesses from necrotic glioblastomas with use of susceptibility-weighted imaging. AJNR Am J Neuroradiol. 2012 Sep;33(8):1534-8. doi: 10.3174/ajnr.A2986. Epub 2012 Mar 15. PMID: 22422181; PMCID: PMC7966558.
- Altman DA, Atkinson DS Jr, Brat DJ. Best cases from the AFIP: glioblastoma multiforme. Radiographics. 2007 May-Jun;27(3):883-8. doi: 10.1148/rg.273065138. PMID: 17495298.