

AMSER Case of the Month

February 2022

38-year-old woman who is 6 weeks postpartum
presents with right breast swelling

Jason Ha, MS2

Penn State Health Milton S. Hershey Medical Center

Angela I. Choe, MD

Penn State Health Milton S. Hershey Medical Center

Patient Presentation

- **HPI:** 38-year-old female who was 6-weeks postpartum presented with swelling of the right breast. She was unable to breast feed on this side.
- **Family history:** Bladder cancer in MGM, Colon/rectal cancer in PGM, Melanoma in father, Prostate cancer in paternal uncle
- **OB/GYN history:** G2P2 at 6 weeks postpartum from vaginal delivery. First live birth at age 24
- **Medical History:** Heartburn, Celiac disease, fibromyalgia, exercise induced asthma
- **Surgical History:** Sling procedure of bladder neck, tonsillectomy, adenoidectomy
- **Physical exam:** Two masses were noted in the right breast in the upper outer quadrant and in the lower outer quadrant. There were enlarged right axillary lymph nodes

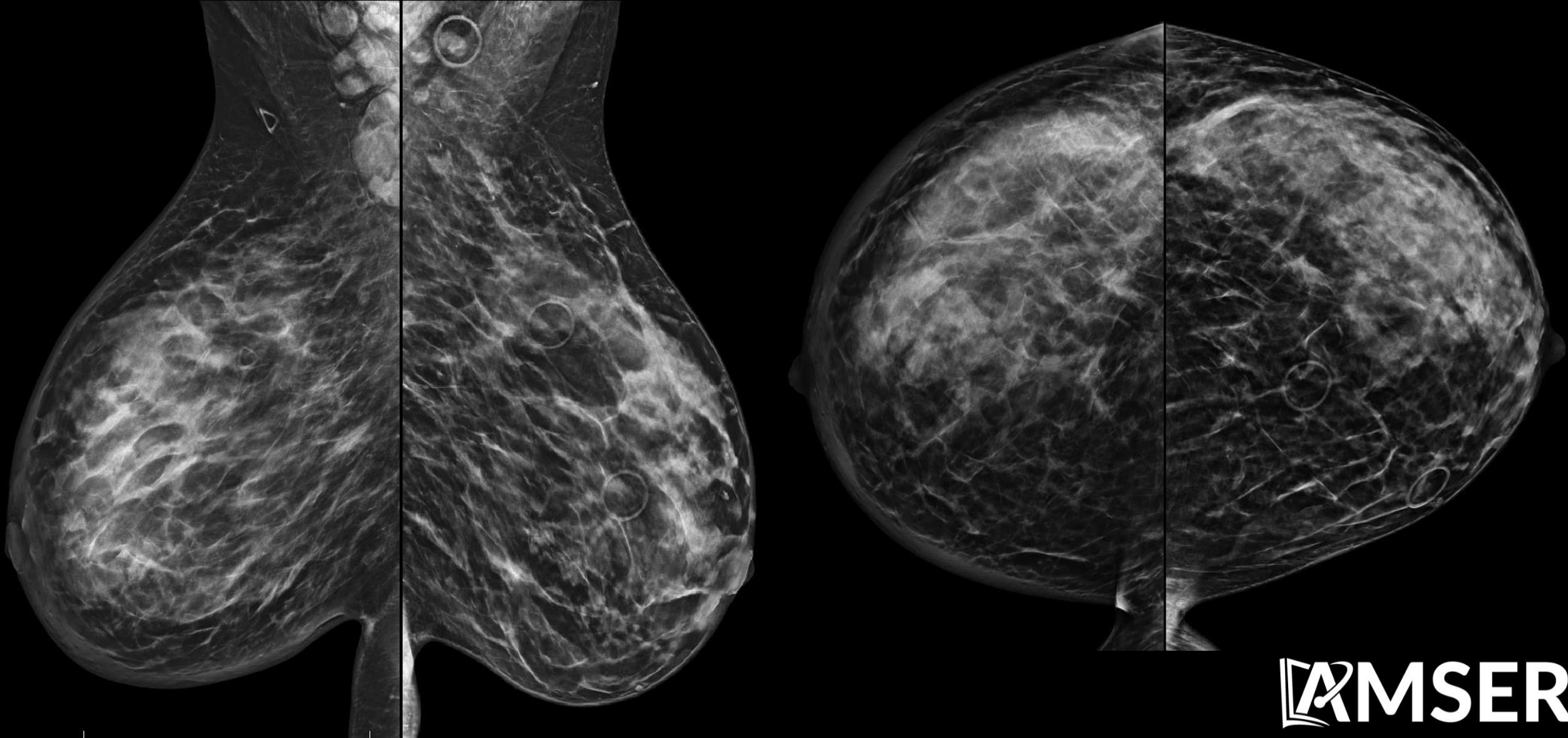
What Imaging Should We Order?

ACR Appropriateness Criteria for work up of palpable breast masses in younger women

Variant 11: Palpable breast mass. Female, 30 to 39 years of age, initial evaluation. (See [Appendix 3](#) for additional steps in the workup of these patients.)

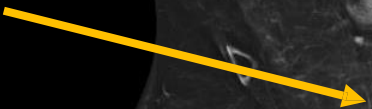
Radiologic Procedure	Rating	Comments	RRL*
US breast	8	If imaged initially with US, see Variants 7-10 for additional imaging.	○
Mammography diagnostic	8	If imaged initially with mammography, see Variants 2-5. See references [14,15].	⊗⊗
Digital breast tomosynthesis diagnostic	8	See references [16-20].	⊗⊗
MRI breast without and with IV contrast	2	See references [4,49].	○
MRI breast without IV contrast	1		○
FDG-PEM	1		⊗⊗⊗⊗
Sestamibi MBI	1		⊗⊗⊗
Image-guided core biopsy breast	1		Varies
Image-guided fine-needle aspiration breast	1		Varies
Rating Scale: 1,2,3 Usually not appropriate; 4,5,6 May be appropriate; 7,8,9 Usually appropriate			*Relative Radiation Level

Findings (unlabeled)



Findings (labeled)

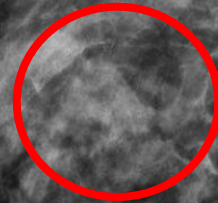
Right axillary
Lymphadenopathy



Skin thickening




asymmetry



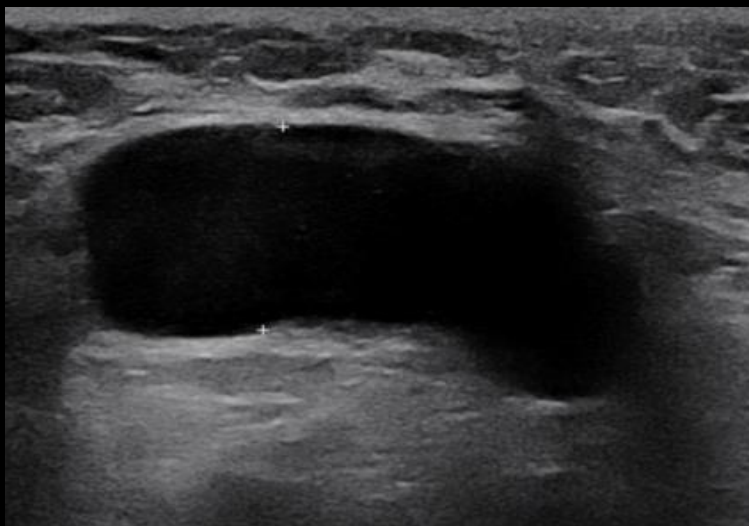
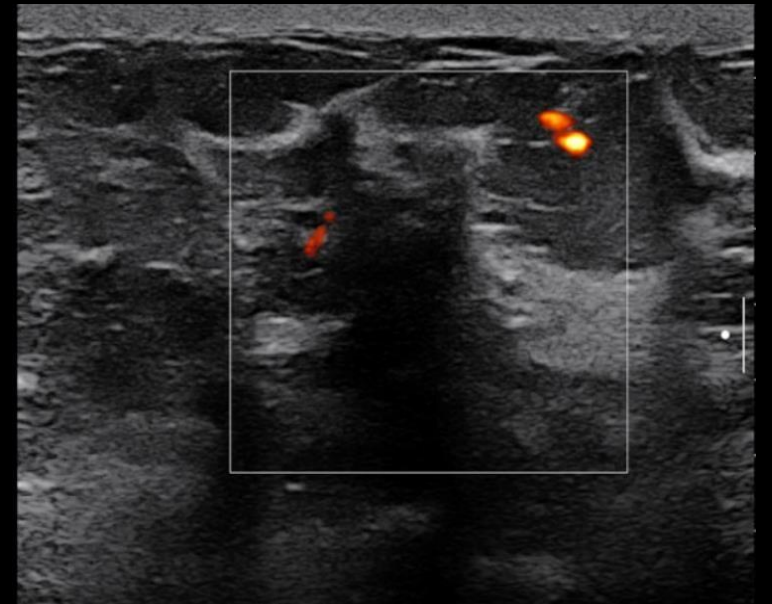
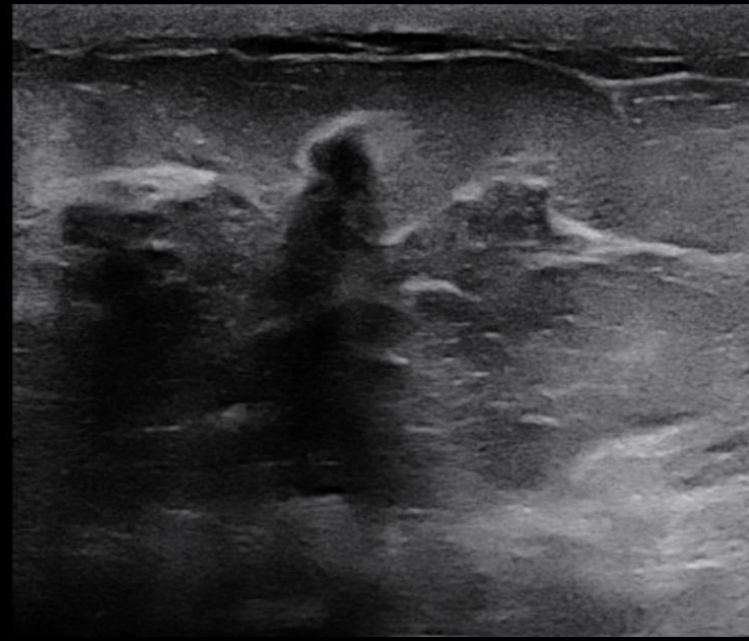
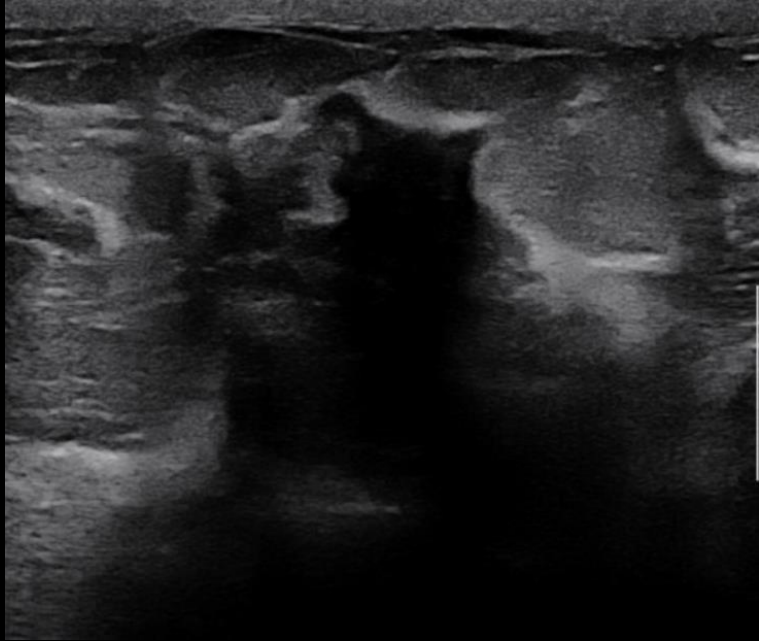Skin thickening
Trabecular thickening



Skin thickening

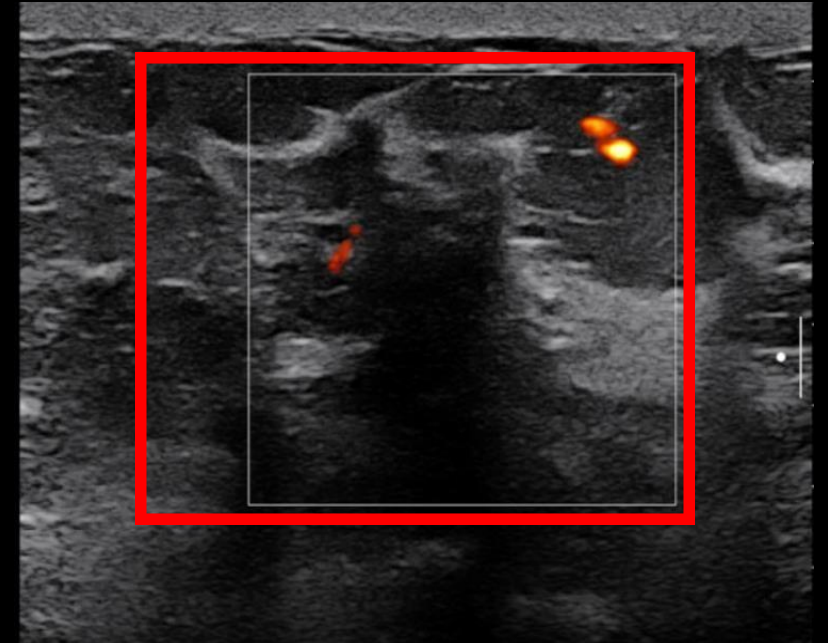
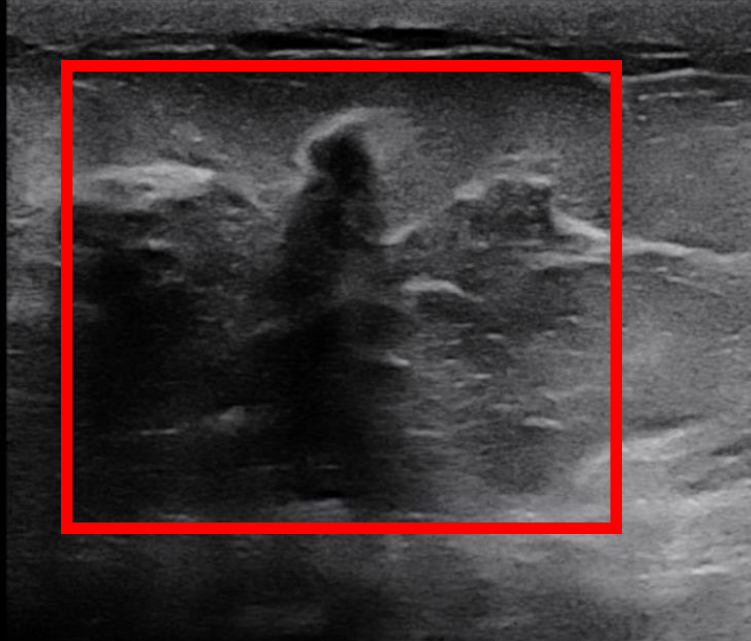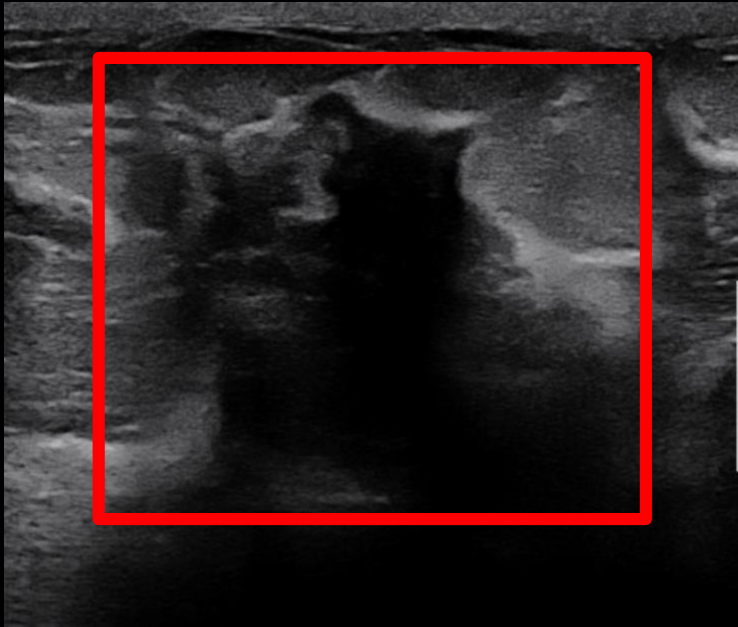


Findings (unlabeled)

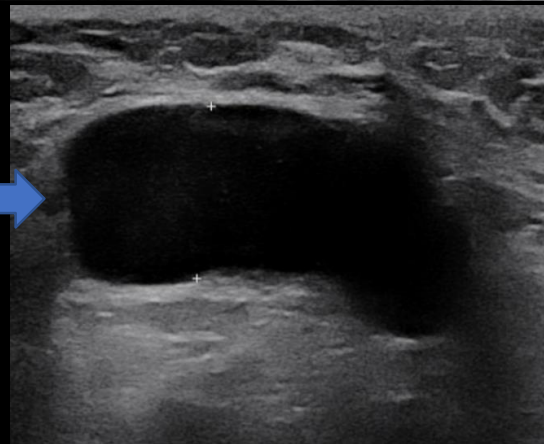


Findings (labeled)

Irregular shadowing mass with internal vascularity



Abnormal right
Axillary lymph node



Final Dx:

Inflammatory Breast Cancer (IBC)

Inflammatory breast cancer

- Inflammatory breast cancer (IBC) is a rare and aggressive form of breast cancer characterized by diffuse dermatologic erythema and edema (peau d'orange)
- Accounts for 0.5 – 2% of invasive breast cancers in the United States
- Diagnosis is based upon characteristic clinical presentation as well as the presence of invasive carcinoma on breast core needle biopsy
- IBC is diagnosed at an earlier age compared to locally advanced breast cancer, median 59 vs. 66 years

IBC Imaging appearance

- Suspected IBC should be imaged with diagnostic mammogram on the affected side and screening mammogram on the contralateral side, with accompanying ultrasound of the breast and regional lymph nodes
- The typical mammographic appearance of IBC includes diffuse enlargement of the breast, stromal coarsening, diffuse increased density, skin thickening, and enlarged lymph nodes
- Ultrasound can identify the biopsy target and guide percutaneous core biopsy

IBC: Prognosis and treatment

- IBC is associated with poor prognosis and high risk of early recurrence
- The 5-year survival rate is 56% for regional IBC and 19% for IBC with distant metastases
- Standard treatment includes neoadjuvant chemotherapy, mastectomy, and postmastectomy radiation

References

1. Anderson, W. F., Schairer, C., Chen, B. E., Hance, K. W., & Levine, P. H. (2006). Epidemiology of inflammatory breast cancer (IBC)1. *Breast Disease*, 22(1), 9–23. <https://doi.org/10.3233/bd-2006-22103>
2. *Inflammatory breast cancer: Clinical features and treatment*. UpToDate. (n.d.). Retrieved December 9, 2021, from <https://www.uptodate.com/contents/inflammatory-breast-cancer-clinical-features-and-treatment#!>
3. Yeh, E. D., Jacene, H. A., Bellon, J. R., Nakhli, F., Birdwell, R. L., Georgian-Smith, D., Giess, C. S., Hirshfield-Bartek, J., Overmoyer, B., & Van den Abbeele, A. D. (2013). What radiologists need to know about diagnosis and treatment of inflammatory breast cancer: A multidisciplinary approach. *RadioGraphics*, 33(7), 2003–2017. <https://doi.org/10.1148/rg.337135503>
4. Tai, P., Yu, E., Shiels, R., Pacella, J., Jones, K., Sadikov, E., & Mahmood, S. (2005). Short- and long-term cause-specific survival of patients with inflammatory breast cancer. *BMC Cancer*, 5(1). <https://doi.org/10.1186/1471-2407-5-137>
5. *Inflammatory breast cancer: Details, diagnosis, and signs*. American Cancer Society. (n.d.). Retrieved December 9, 2021, from <https://www.cancer.org/cancer/breast-cancer/about/types-of-breast-cancer/inflammatory-breast-cancer.html>.