

AMSER Case of the Month

November 2022

74-Year-Old Female with Worsening Right Hip Pain

Gilbert Lanoue, MS4

Virginia Commonwealth University School of Medicine

Yuije Qiao, M.D.

Virginia Commonwealth University School of Medicine



Patient Presentation

- **HPI:** 74-year-old woman presents to her PCP with a 1-week history of R-sided groin pain. She has difficulty laying on the affected side, struggles significantly walking upstairs, and walks with an occasional limp. She denies weakness, numbness, tingling, or recent trauma.
- **PMHx:** Obesity, Gout, HTN, and HLD.
- **Meds:** Allopurinol and Naproxen.

Patient Presentation

- **Physical Exam:** Vitals: T: 37C, BP= 133/60, P= 74, RR= 16, SPO2 = 99%, Pain = 7/10.
- **General:** Alert and oriented, No acute distress.
- **Neurologic:** Alert, Oriented.
- **Right Hip:** Tenderness palpation of the greater trochanter. Pain with resisted side-lying hip abduction. 5/5 abduction strength. Pain with figure 4 positioning. Negative impingement test. Negative straight leg raise.
- **Relevant Labs:** Hgb= 13.0, WBC = 7.3, %Neutrophils = 65%, ESR = 16 (0-20), **CRP = 0.8 (0.0 – 0.5).**

What Imaging Should We Order?

Select the applicable ACR Appropriateness Criteria

Variant 1: Acute hip pain. Fall or minor trauma. Suspect fracture. Initial imaging.

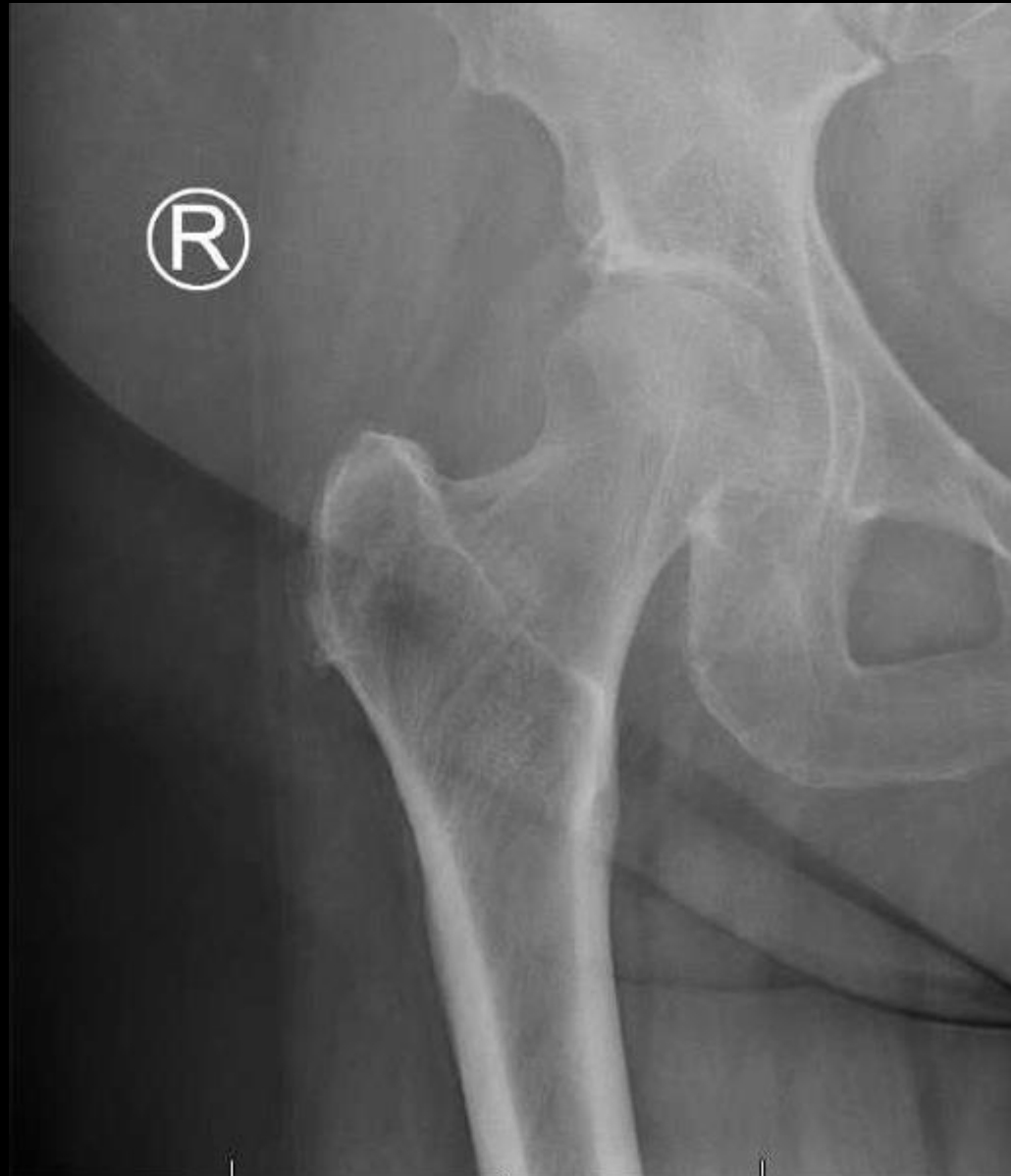Procedure	Appropriateness Category	Relative Radiation Level
Radiography hip	Usually Appropriate	☼☼☼
Radiography pelvis	Usually Appropriate	☼☼
Radiography pelvis and hips	Usually Appropriate	☼☼☼
CT pelvis and hips with IV contrast	Usually Not Appropriate	☼☼☼
CT pelvis and hips without and with IV contrast	Usually Not Appropriate	☼☼☼☼
CT pelvis and hips without IV contrast	Usually Not Appropriate	☼☼☼
MRI pelvis and affected hip without and with IV contrast	Usually Not Appropriate	0
MRI pelvis and affected hip without IV contrast	Usually Not Appropriate	0
Bone scan hips	Usually Not Appropriate	☼☼☼
US hip	Usually Not Appropriate	0



This imaging modality was ordered by the PCP.

Findings (unlabeled)

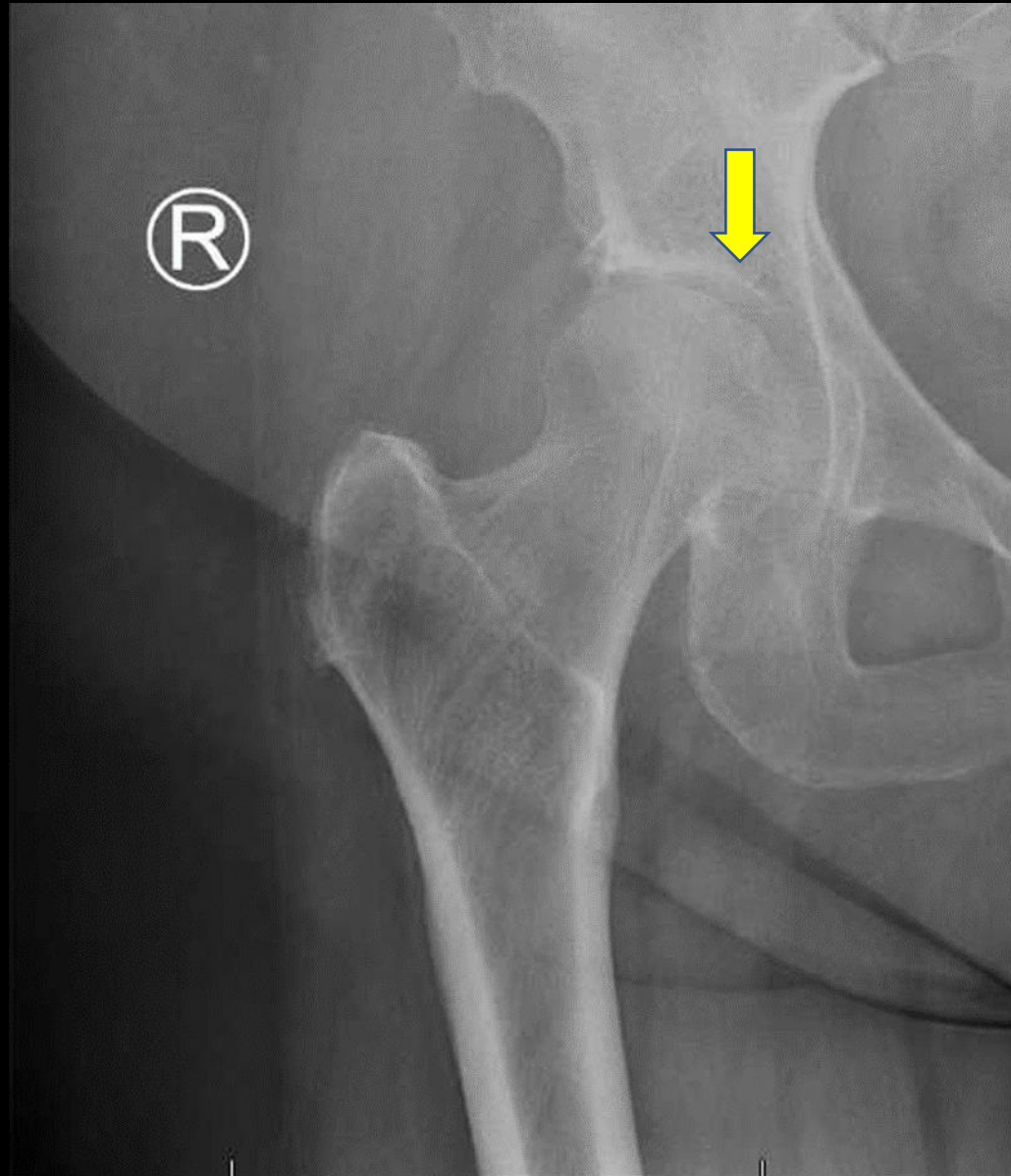
Right AP Plain Film X-Ray



Findings: (labeled)

Right AP Plain Film X-Ray

Degenerative changes. No acute fracture or dislocation.

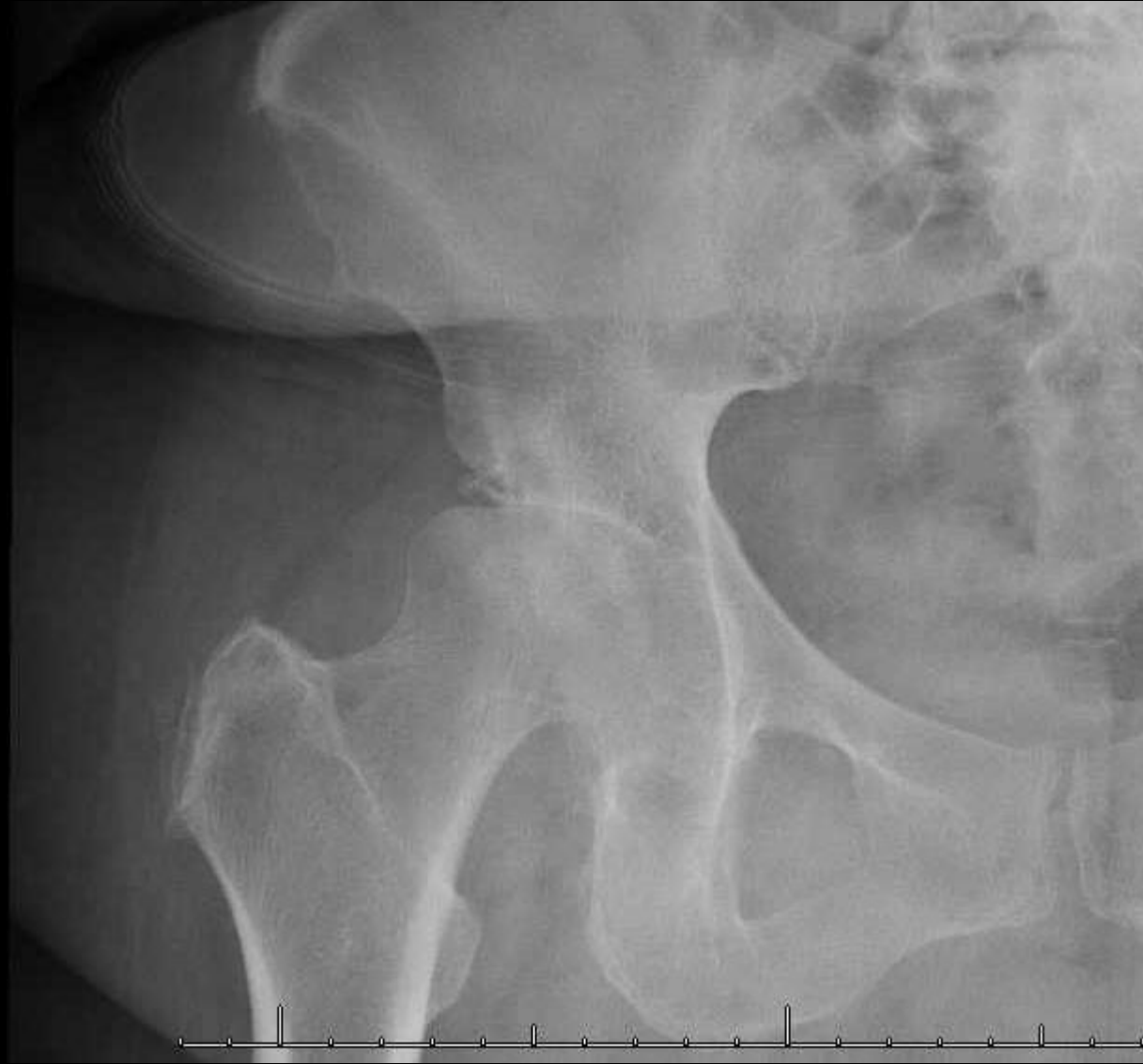

Follow-Up Visit

- The patient was treated conservatively with NSAIDs and physical therapy. After failing conservative therapy, the patient was referred to Orthopedics 8 months later due to persistent and progressive R-sided groin pain. Repeat plain film X-rays were ordered.

Findings: (unlabeled)

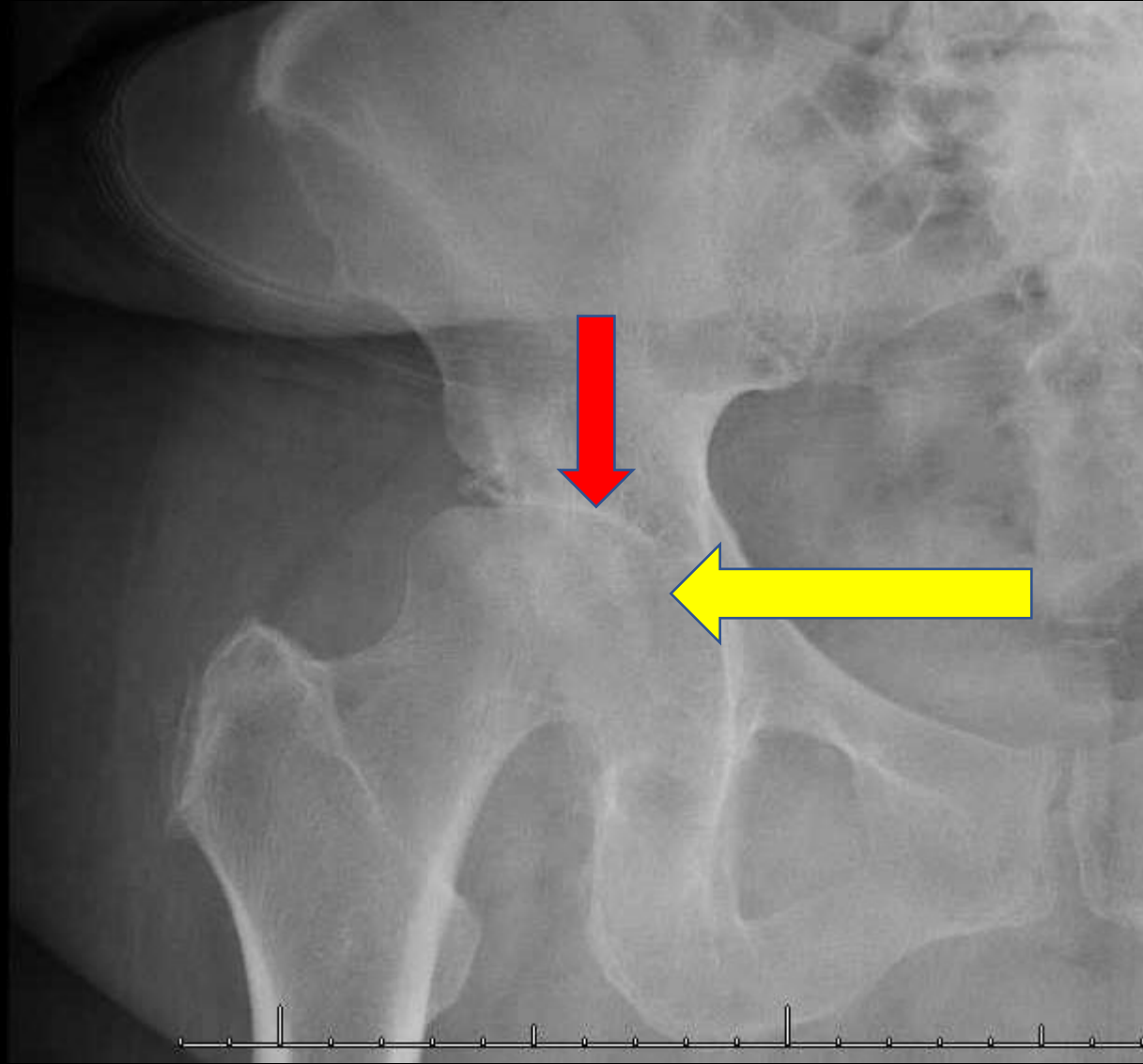
Right AP Plain Film X-Ray



Findings: (labeled)

Right AP Plain Film X-Ray

1. Severe degenerative changes of the right femoroacetabular joint. (yellow arrow)
2. Subchondral sclerosis, severe joint space narrowing, and remodeling of the acetabulum and femoral head. (red arrow)



What Imaging Should We Order?

Select the applicable ACR Appropriateness Criteria

Variant 2:

Suspected septic arthritis or soft tissue infection. Initial radiographs normal or with findings suggestive of joint effusion or soft tissue swelling. Next imaging study.

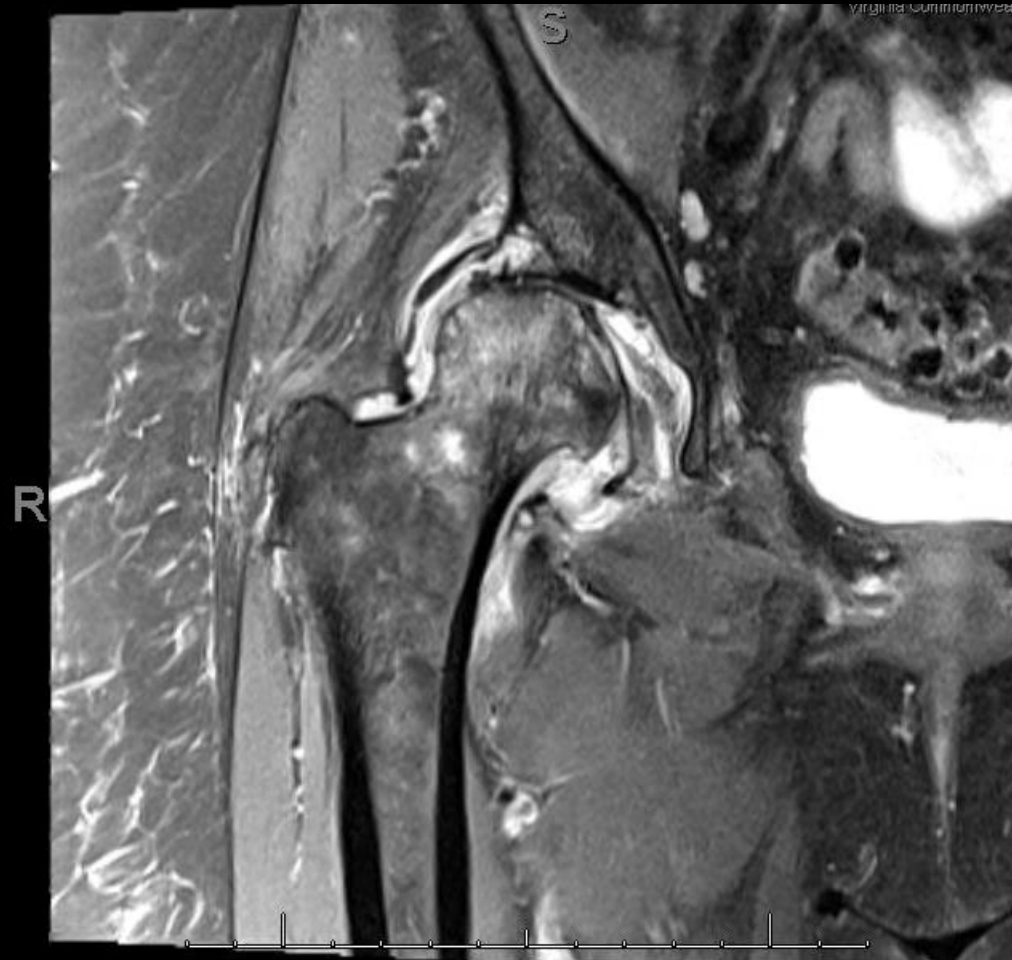
Procedure	Appropriateness Category	Relative Radiation Level
US area of interest	Usually Appropriate	0
Image-guided aspiration area of interest	Usually Appropriate	Varies
MRI area of interest without and with IV contrast	Usually Appropriate	0
MRI area of interest without IV contrast	Usually Appropriate	0
CT area of interest with IV contrast	Usually Appropriate	Varies
CT area of interest without IV contrast	May Be Appropriate	Varies
3-phase bone scan area of interest	Usually Not Appropriate	☢☢☢
CT area of interest without and with IV contrast	Usually Not Appropriate	Varies



This imaging modality was ordered by the Orthopedic Surgeon

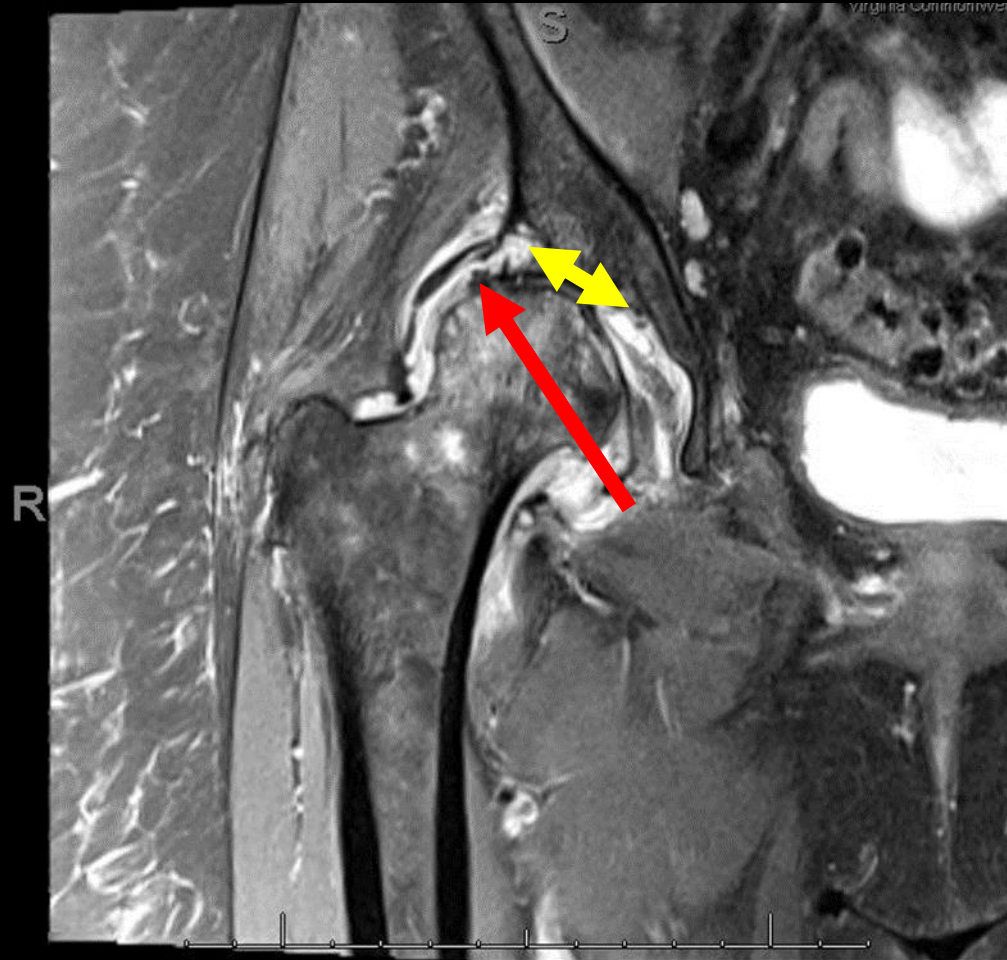
Findings (unlabeled)

Right PD-Weighted Coronal View



Findings: (labeled)

Right PD-Weighted Coronal View



Severe arthropathy of the right hip with grade IV chondromalacia significantly progressed from previous imaging. Subchondral collapse of the right femoral head (red arrow) with adjacent marrow edema, multifocal labral tearing (yellow arrow), small joint effusion, moderate synovitis, and pericapsular edema.

Final Dx:

Rapidly Progressive Osteoarthritis (RPOA)

Case Discussion

- **Definition:** Initially defined by Lequesne in 1970, RPOA is characterized by rapid chondrolysis of $> 2\text{mm}$ in one year or 50% joint space-narrowing in one year without any evidence of another form of rapidly destructive arthropathy.
- **Epidemiology:** Rapidly progressive osteoarthritis is a rare subtype of osteoarthritis that typically favors elderly women and is a diagnosis of exclusion.
- **Pathophysiology:** Although the exact pathophysiologic mechanism of RPOA remains unclear, femoral head destruction within 12 months of the onset of pain has been associated with higher serum levels of matrix metalloproteinase-3 (MMP-3) and higher synovial levels of TNF-alpha and IL-6.

Case Discussion

- **Symptoms:** In the majority of cases, RPOA is unilateral. It presents with hip/groin pain that progressively affects quality of life.
- **Workup:** Initial laboratory workup should include a white blood cell count, and rheumatic serology studies coupled with ESR and CRP levels. If elevated, then joint aspiration should be performed to further narrow the differential. If these studies are not consistent with infection, then RPOA should be favored as the diagnosis.

Case Discussion

- **Imaging:** Initially, radiographs of RPOA may show normal anatomy. Follow-up radiographs often demonstrate destruction of the femoral head and acetabulum with sclerosis, subchondral cysts, and minimal to no osteophytes. The most popularly adopted diagnostic criteria, includes progressive chondrolysis exceeding 2 mm per year or the loss of more than 50% joint space within 1 year. MR imaging typically reveals a diffuse area of low intensity on T1WI and high intensity on T2WI in the proximal femur, including the femoral neck and head, which suggests extensive bone marrow edema.
- **Treatment:** Total hip replacement is the treatment of choice for RPOA.
- **Outcomes:** Misdiagnosis and delayed treatment can lead to worse clinical outcomes, but total hip replacement is curative.

References:

1. Boutry, Nathalie, et al. "Rapidly destructive osteoarthritis of the hip: MR imaging findings." *American Journal of Roentgenology* 179.3 (2002): 657-663.
2. Yasuda, T., Matsunaga, K., Hashimura, T., Tsukamoto, Y., Sueyoshi, T., Ota, S., Fujita, S., & Onishi, E. (2020). Characterization of rapidly progressive osteoarthritis of the hip in its early stage. *European journal of rheumatology*, 7(3), 130–134.
<https://doi.org/10.5152/eurjrheum.2020.19159>
3. Batra, S., Batra, M., McMurtrie, A. et al. Rapidly destructive osteoarthritis of the hip joint: a case series. *J Orthop Surg Res* 3, 3 (2008). <https://doi.org/10.1186/1749-799X-3-3>
4. Fukui, K., Kaneuji, A., Fukushima, M., & Matsumoto, T. (2015). Early MRI and intraoperative findings in rapidly destructive osteoarthritis of the hip: a case report. *International Journal of Surgery Case Reports*, 8, 13-17.
5. Flemming, D. J., & Gustas-French, C. N. (2017). Rapidly progressive osteoarthritis: a review of the clinical and radiologic presentation. *Current rheumatology reports*, 19(7), 1-6.
6. Rosenberg, Z. S., Shankman, S. T. E. V. E. N., Steiner, G. C., Kastenbaum, D. K., Norman, A., & Lazansky, M. G. (1992). Rapid destructive osteoarthritis: clinical, radiographic, and pathologic features. *Radiology*, 182(1), 213-216.
7. Lequesne, M. (1970). La coxarthrose destrctice rapide. *Rheumatologie*, 22, 21