

AMSER Case of the Month: February 2019

57-year-old male with retrosternal dysphagia

By Scott Schmalzried, MS-III
Lake Erie College of Osteopathic Medicine

Matthew Hartman, M.D.
Medical Student Coordinator; Allegheny Health Network



Patient Presentation

- CC/HPI: 57-year-old male presented to physician with worsening retrosternal dysphagia and odynophagia over a two year period. Patient reported frequent regurgitation, an approximately 50 lb. weight loss over the two year timeframe, and modification of his diet to more easily swallowed solids and liquids.
- PMHx: No relevant Hx
- PSHx: No relevant Hx
- Past Medications: PPI
- Physical Exam: No masses palpated

What Imaging Should We Order?

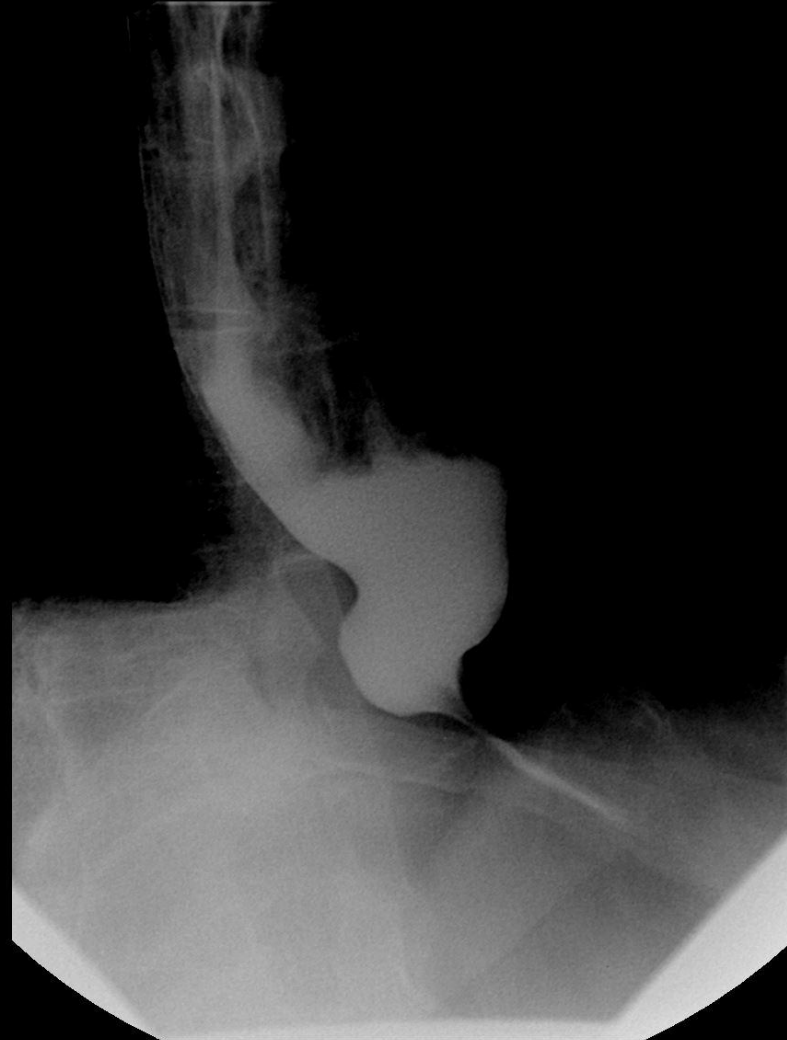
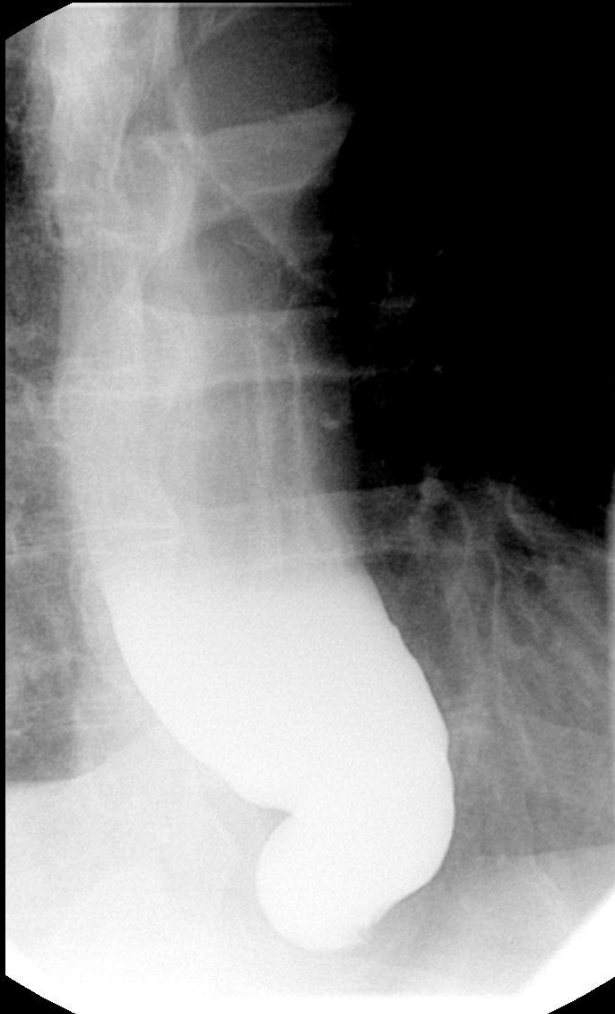
ACR Appropriateness Criteria: Retrosternal dysphagia

Variant 3: Retrosternal dysphagia in immunocompetent patients.

Radiologic Procedure	Rating	Comments	RRL*
X-ray biphasic esophagram	8	Endoscopy and biphasic esophagram are both excellent diagnostic tests in this setting.	☼ ☼ ☼
X-ray barium swallow single contrast	6	This procedure is probably indicated if the patient is not capable of doing anything except swallowing.	☼ ☼ ☼
X-ray barium swallow modified	4		☼ ☼ ☼
X-ray pharynx dynamic and static imaging	4	Esophageal examination is also necessary.	☼ ☼ ☼
Tc-99m transit scintigraphy esophagus	4		☼ ☼ ☼
Rating Scale: 1,2,3 Usually not appropriate; 4,5,6 May be appropriate; 7,8,9 Usually appropriate			*Relative Radiation Level

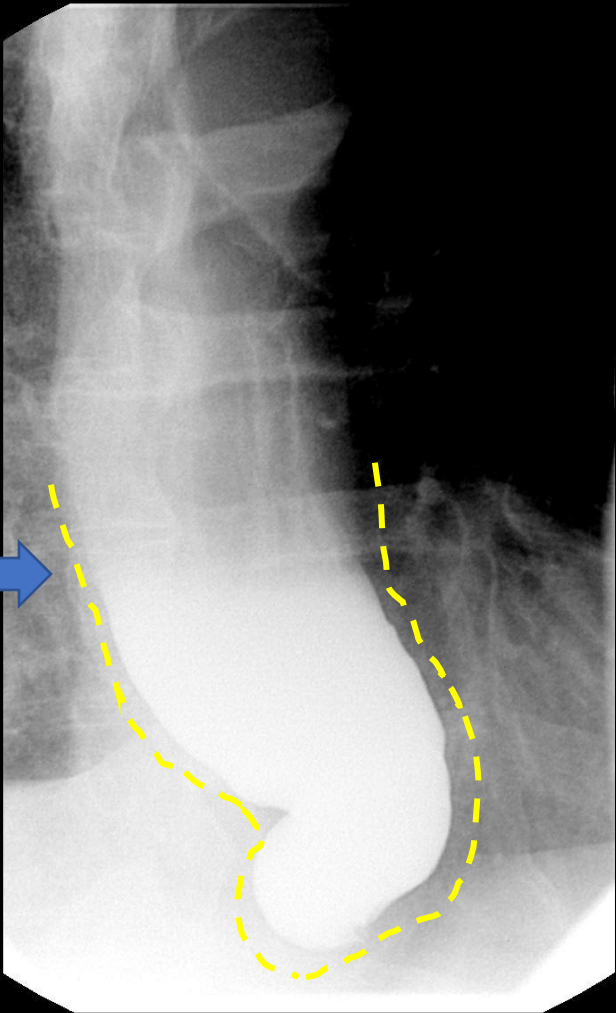
This imaging modality was ordered by the physician

Esophagram

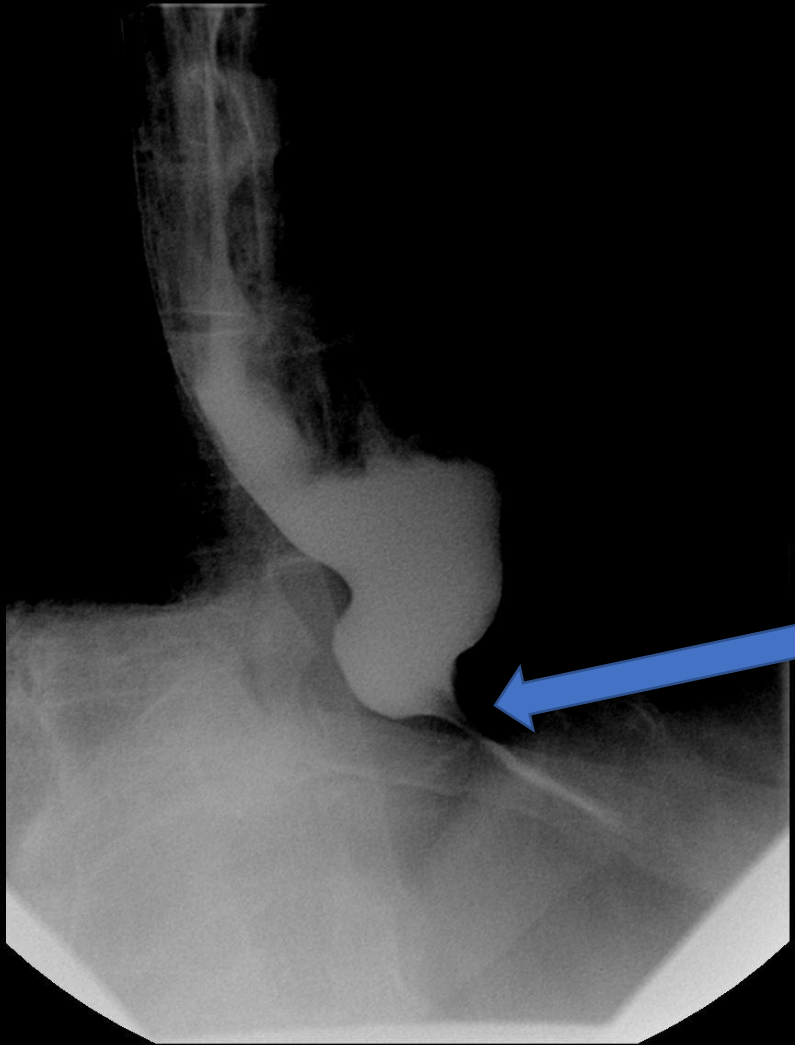



Esophagram

Esophageal
dilation



Bird's beak
narrowing



Final Dx:

Achalasia

Achalasia

- Results from progressive degeneration of ganglion cells in the myenteric plexus in the esophageal wall, leading to failure of relaxation of the lower esophageal sphincter, accompanied by a loss of peristalsis in the distal esophagus. May be primary or secondary.
 - Cause of primary achalasia is unknown
- Incidence
 - Approximately 1.6 cases per 100,000 individuals and prevalence of 10 cases per 100,000 individuals. Men and women are affected with equal frequency. Usually diagnosed in patients between the ages of 25 and 60 years.
- Presentation
 - Dysphagia to solids and liquids, weight loss, difficulty belching, heartburn, chest pain/discomfort, and aspiration. Usually insidious in onset.
- Differential diagnoses
 - GERD, pseudoachalasia (direct malignant invasion of neural plexus or paraneoplastic syndrome), esophageal motility disorders (diffuse esophageal spasm, scleroderma) stricture

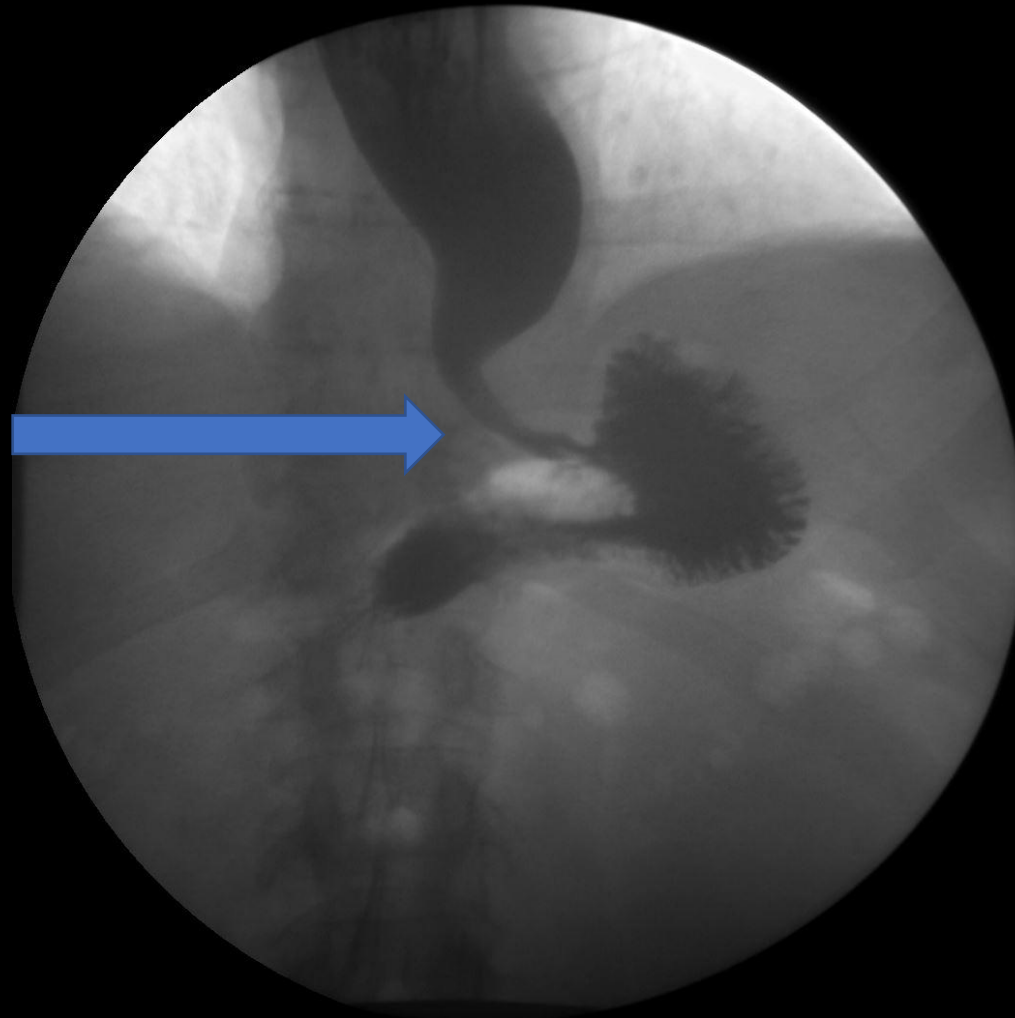
Achalasia

- Characteristics on barium esophagram
 - Dilation of the esophagus (may be angulated, and tortuous, giving it a sigmoid shape), narrow EGJ with "bird-beak" appearance caused by the persistently contracted LES, aperistalsis, and delayed emptying of barium.
- Treatment
 - Pneumatic dilation, botulinum toxin injection, surgical myotomy, and per-oral endoscopic myotomy (POEM)*
- Complications
 - Esophageal SCC, esophageal candidiasis, aspiration, acute airway obstruction

*Treatment performed in this patient

Esophagram – Post-treatment

Note the marked improvement of passage of oral contrast from esophagus into stomach, which occurred immediately as compared to a significant delay prior to POEM



References:

- ACR appropriateness criteria: <https://acsearch.acr.org/docs/69471/Narrative/>
- <https://radiopaedia.org/articles/bird-beak-sign-oesophagus>
- <https://radiopaedia.org/articles/achalasia>
- https://www.uptodate.com/contents/approach-to-the-evaluation-of-dysphagia-in-adults?search=dysphagia&source=search_result&selectedTitle=1~150&usage_type=default&display_rank=1
- https://www.uptodate.com/contents/achalasia-pathogenesis-clinical-manifestations-and-diagnosis?search=achalasia&source=search_result&selectedTitle=1~108&usage_type=default&display_rank=1
- https://www.uptodate.com/contents/overview-of-the-treatment-of-achalasia?search=achalasia&source=search_result&selectedTitle=2~108&usage_type=default&display_rank=2
- https://www.uptodate.com/contents/surgical-myotomy-for-achalasia?topicRef=2268&source=see_link