

AMSER Case of the Month: June 2019

83 y/o female with a diffusely tender abdomen



Aaron Jacobson, OMS-IV

West Virginia School of Osteopathic Medicine



Cheryl L Kirby, MD

Albert Einstein Healthcare Network



Patient Presentation

- 83 y/o F brought to emergency department (ED) for altered mental status and lethargy. While in the ED, patient complained of abdominal pain and nausea.
- Past medical history: Breast cancer, DVT on Coumadin, and Hyperlipidemia
- Vitals: Within normal limits (WNL)
- Physical Exam: Abdomen diffusely tender to palpation, worse in the right upper quadrant

Pertinent Labs

- Labs (WNL except):
 - WBC: 14.8
 - INR: 5.6
 - PTT: 55.1
- Nasogastric Tube Placed in ED
 - 1300 cc of bilious fluid

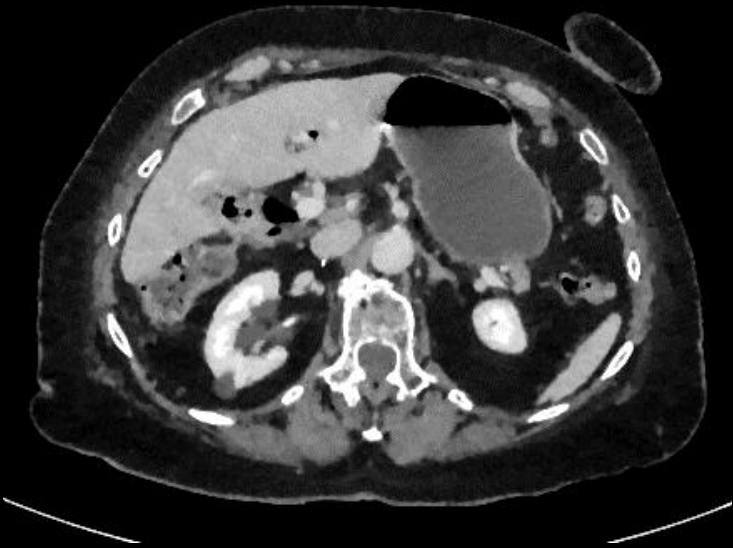
What imaging study should be obtained?

Select the applicable ACR Appropriateness Criteria

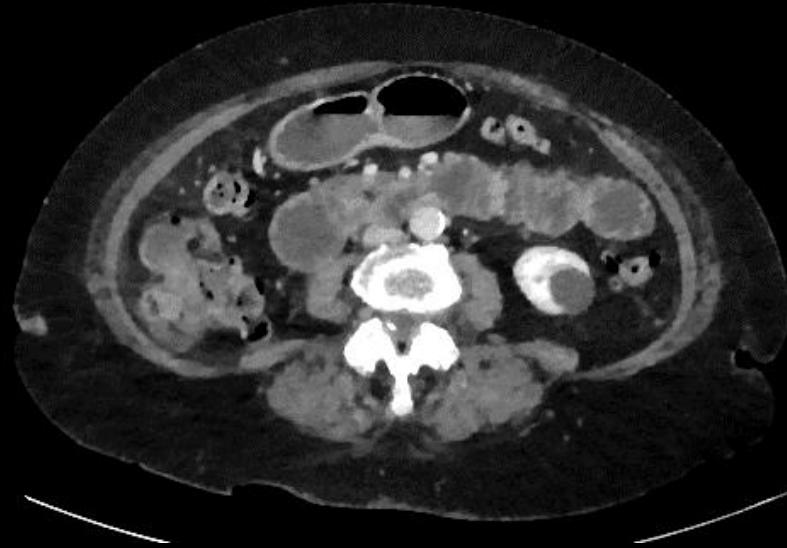Clinical Condition:		Suspected Small-Bowel Obstruction	
Variant 1:		Suspected high-grade small-bowel obstruction (SBO), based on clinical evaluation or initial radiography (if performed).	
Radiologic Procedure	Rating	Comments	RRL*
CT abdomen and pelvis with IV contrast	9	Oral contrast should not be used if high-grade SBO is known or suspected. Oral contrast will not reach the site of obstruction, wastes time, adds expense, can induce further patient discomfort, will not add to diagnostic accuracy, and can lead to complications, particularly vomiting and aspiration.	☒ ☒ ☒ ☒
CT abdomen and pelvis without IV contrast	7	Perform this procedure in patients who have known or suspected high-grade SBO when IV contrast is contraindicated.	☒ ☒ ☒ ☒
MRI abdomen and pelvis without and with IV contrast (routine)	6	MRI is most appropriate in children and younger adult patients who have had multiple prior CT examinations.	0
X-ray abdomen and pelvis	5	Perform this procedure if it has not already been performed.	☒ ☒ ☒
CT abdomen and pelvis without and with IV contrast	4		☒ ☒ ☒ ☒

This imaging modality was ordered by the ER physician

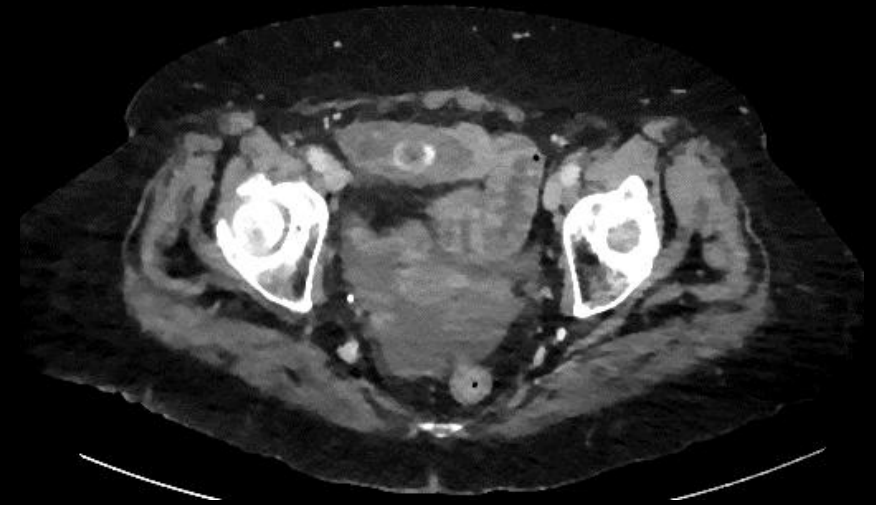Findings (unlabeled)



upper

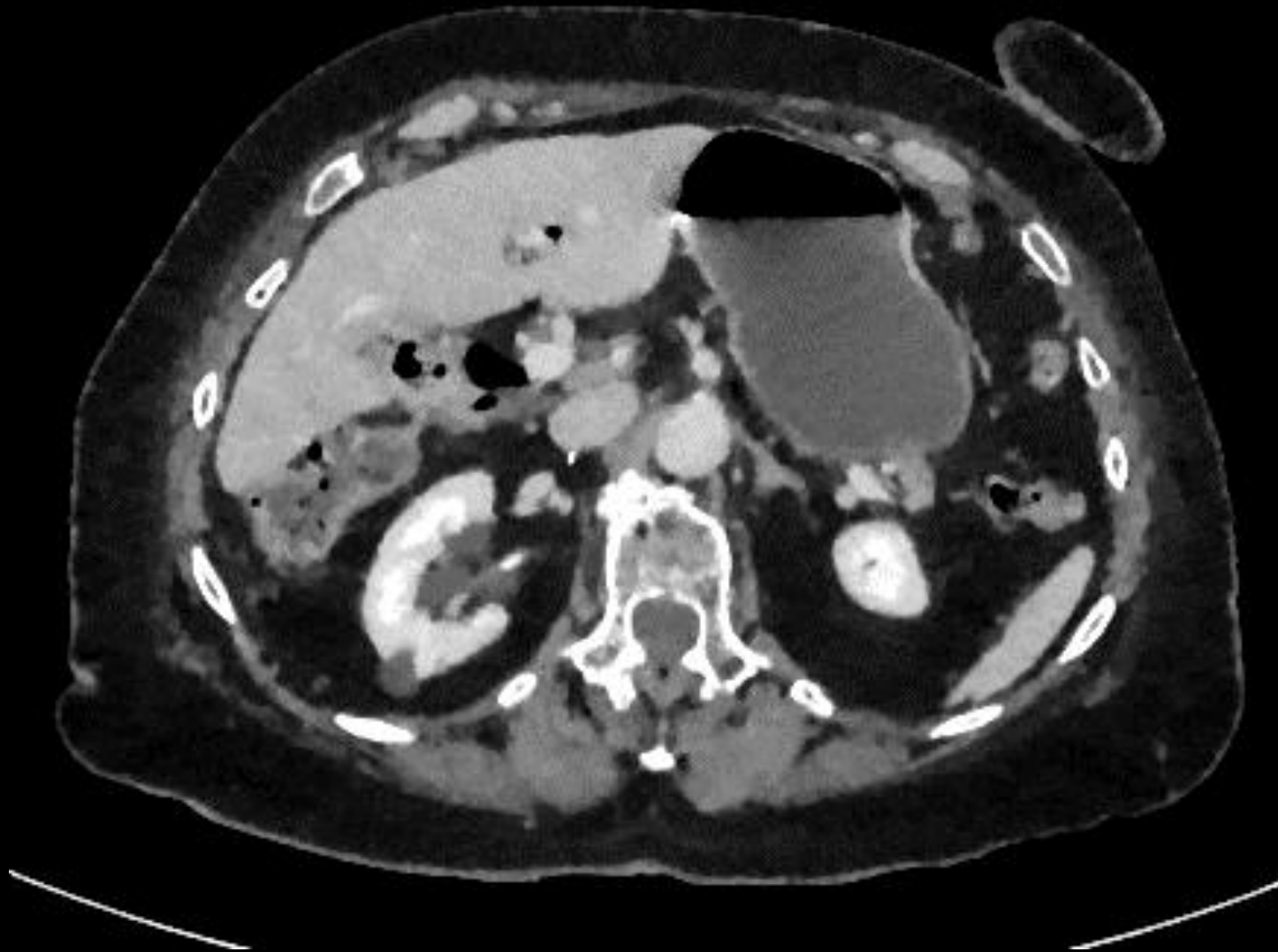


mid

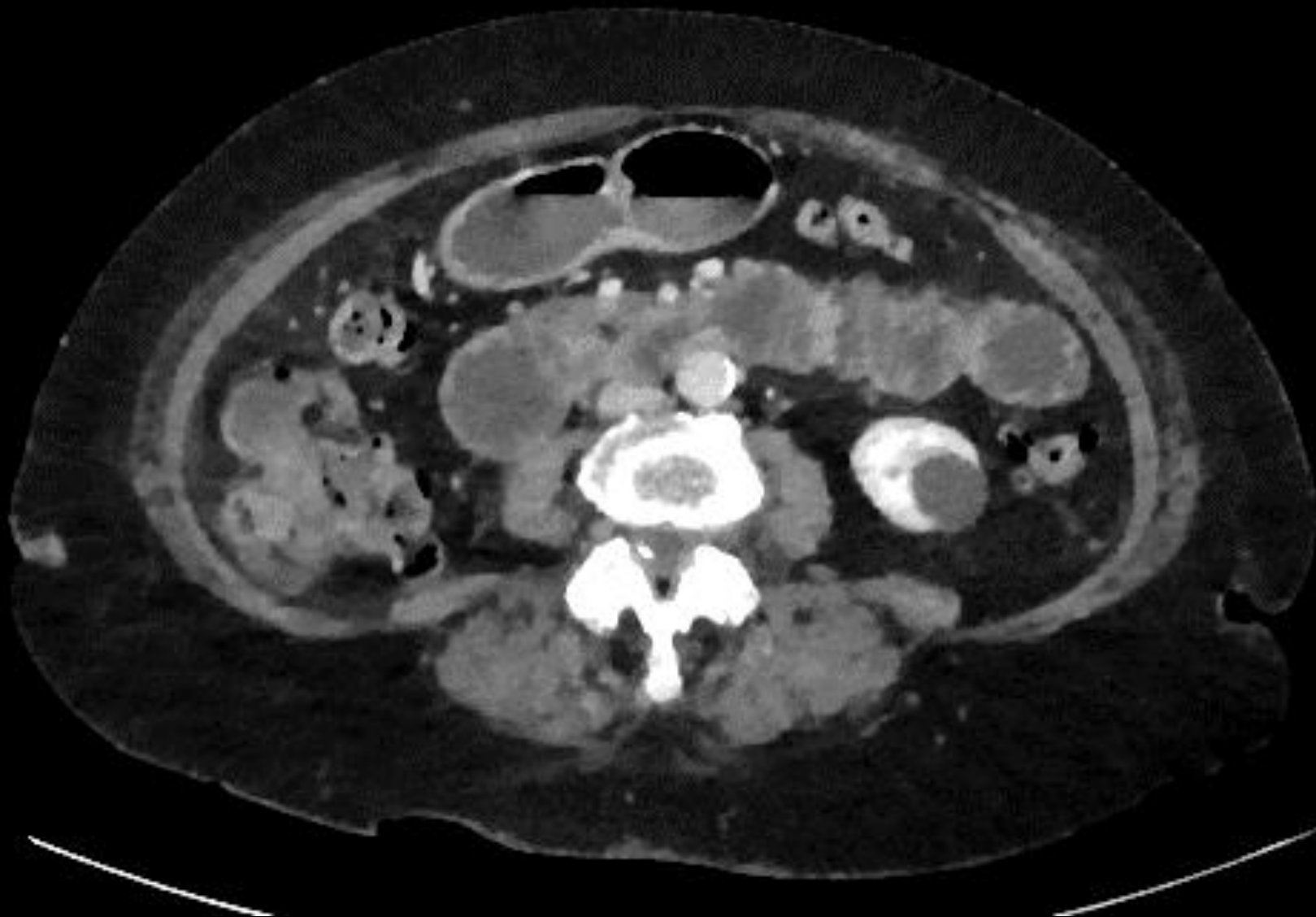

lower

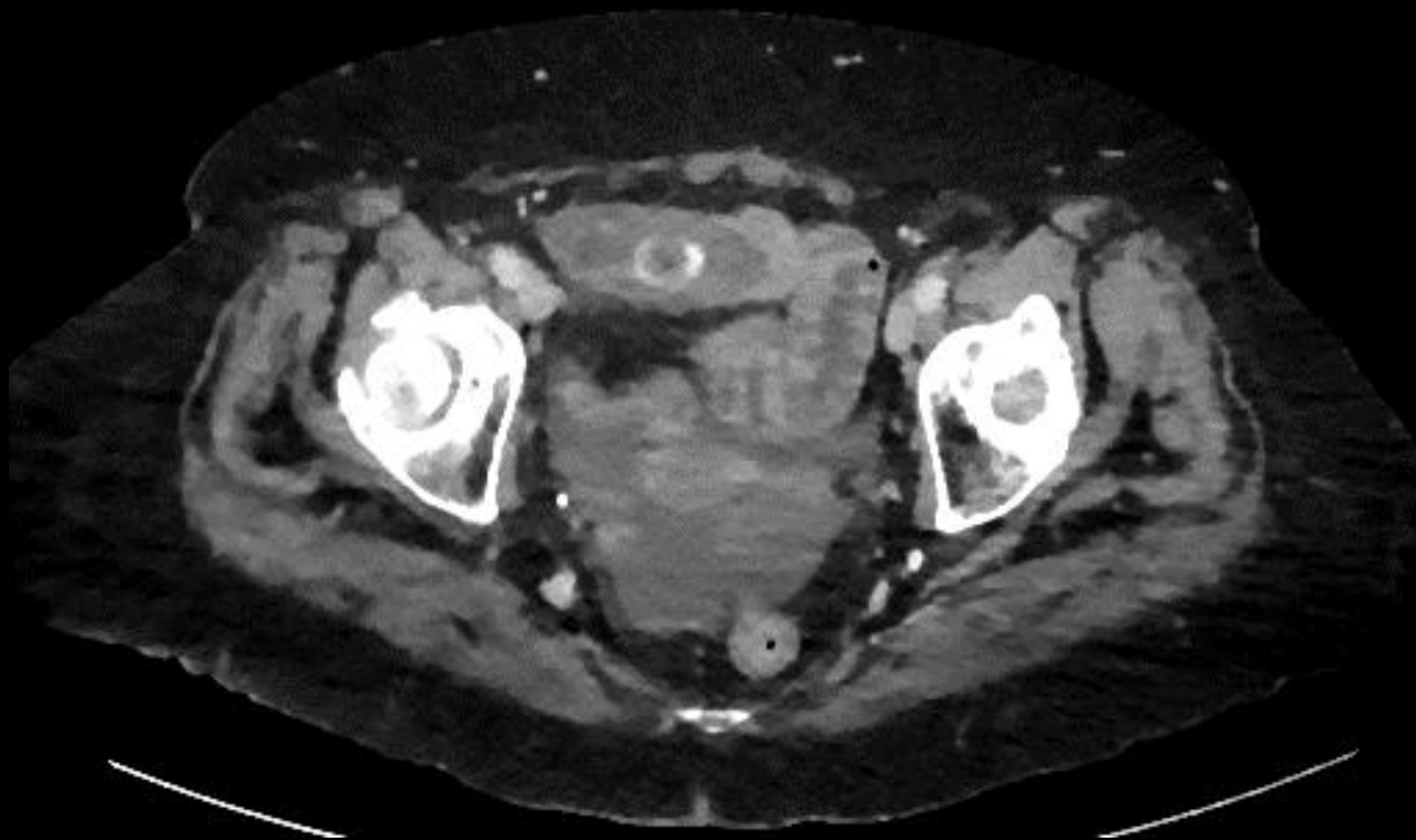Findings Upper (unlabeled)



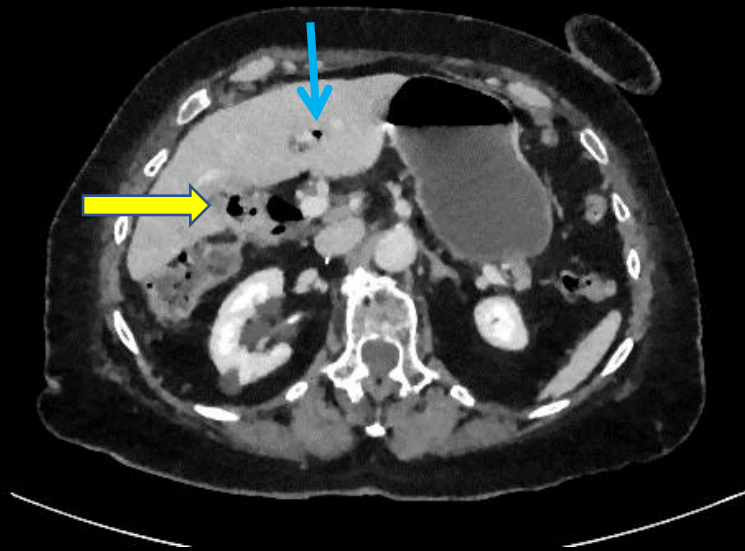
Findings Mid (unlabeled)



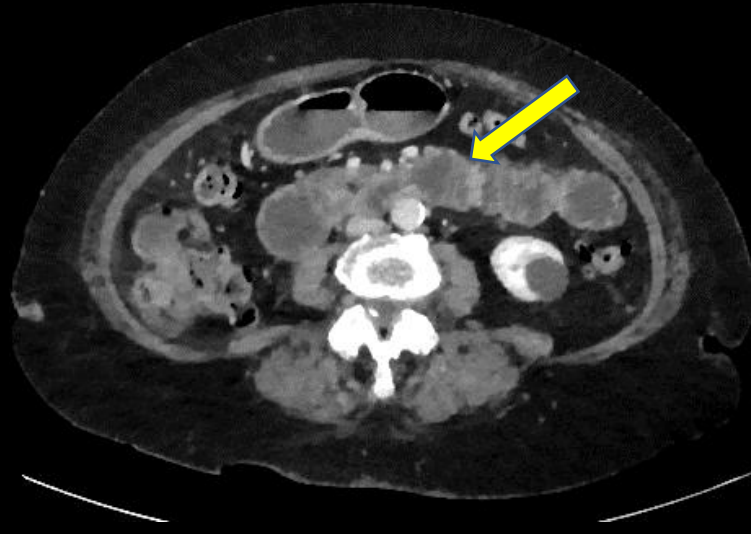
Findings Lower (unlabeled)



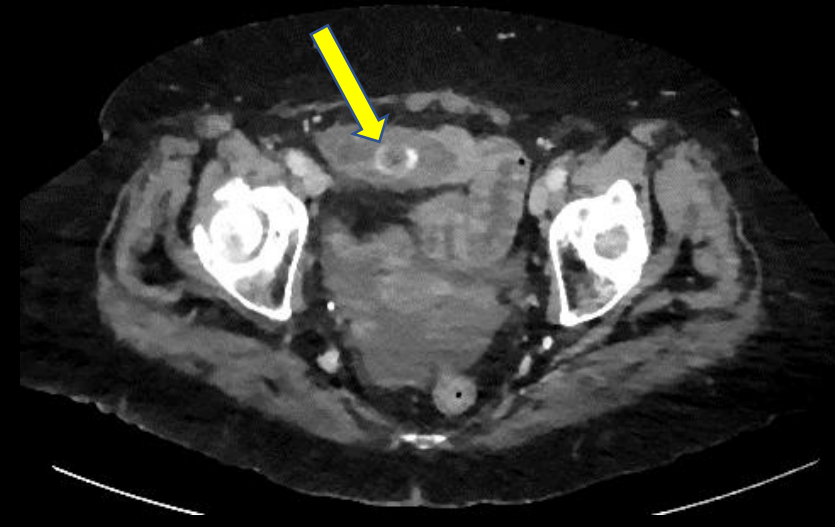
Findings: (labeled)



Cholecystoduodenal fistula/gallbladder with air (yellow arrow) and Air in bile duct (blue arrow)

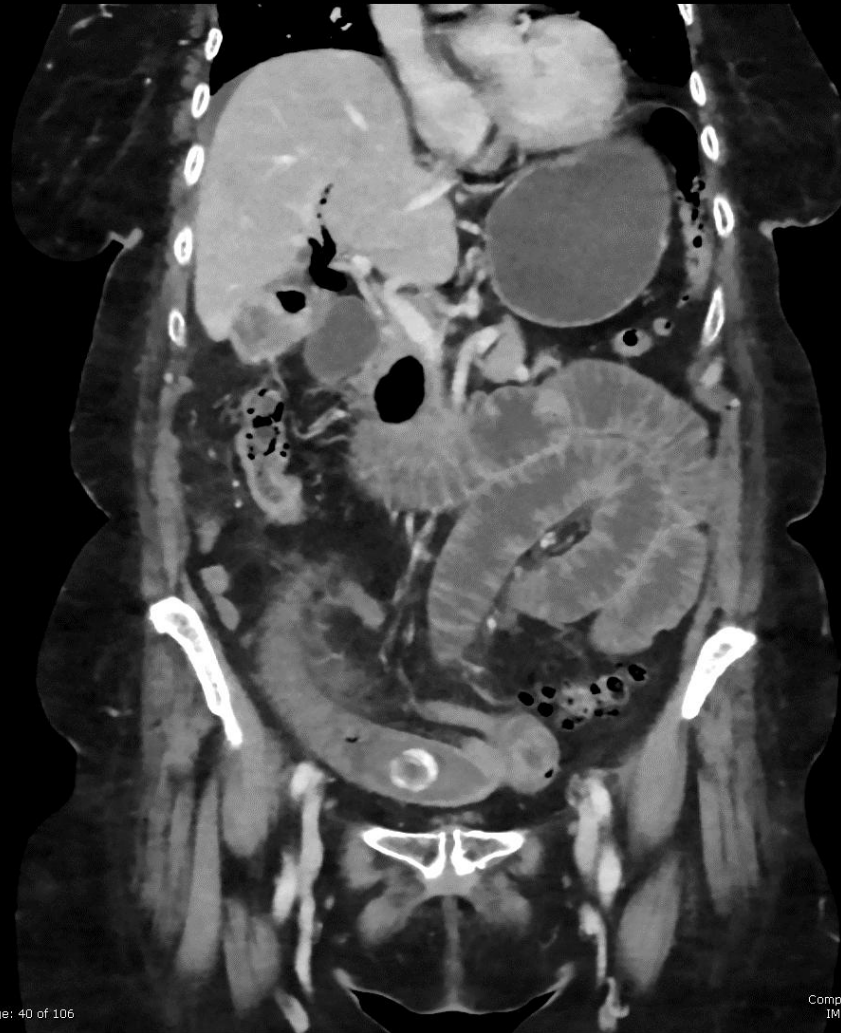

Dilated Small bowel



Mechanically obstructing gallstone

Findings (unlabeled)



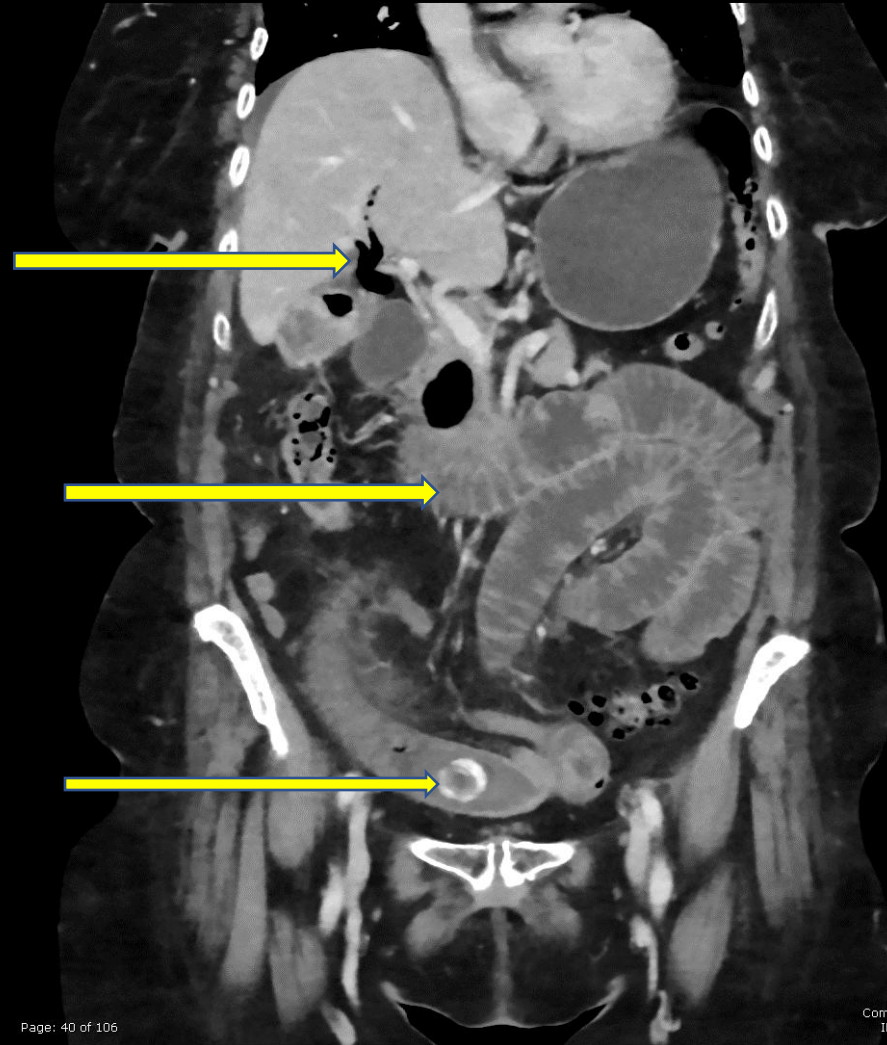
Findings: (labeled)

Rigler's Triad:

Pneumobilia

Dilated Small Bowel

Obstructing Gallstone
In Mid Small Bowel



Final Dx:

Gallstone Ileus

Gallstone Ileus

- Misnomer (not an “ileus”): Represents mechanical bowel obstruction by one or more gallstones. Obstructing gallstone usually measures at least 2-2.5cm in diameter.
- Rare
 - Cause of 1-4% of all mechanical bowel obstructions
 - Seen in only 0.5% of patients with gallstones
- Population: Elderly, F>M
- Pathophysiology - Fistula forms from the gallbladder to the GI tract secondary to recurrent or chronic wall inflammation or chronic stone pressure leading to erosion.
 - Most common fistula: Cholecystoduodenal

Gallstone Ileus

- Gallstone passes to the GI tract and causes mechanical obstruction
 - Most common site of impaction: terminal ileum at ileocecal valve
 - Less common: jejunum, stomach/duodenum (Bouveret), colon
- Symptoms:
 - Nonspecific, related to site of obstruction
 - May be intermittent, secondary to mobile stone causing sporadic obstruction
 - Likely accounts for delay in diagnosis, frequently diagnosed 3-8 days after symptom onset
- Treatment: Controversial. Surgery options vary based on comorbid conditions
 - Enterolithotomy or bowel resection
 - Enterolithotomy, cholecystectomy and fistula closure (one-stage)
 - Indicated for low-risk, American Society of Anesthesiologists (ASA) class I or II patients
 - Enterolithotomy with cholecystectomy performed later (two-stage procedure)
 - Indicated for high-risk, ASA class III or IV patients

Our patient's course:

- Underwent emergent laparotomy with mid small bowel gallstone extraction and small bowel resection with re-anastomosis
- Preoperatively, the patient was notified that the gallbladder would be addressed at a later date.
- Extracted gallstone from small bowel measured 3 x 2.2cm.
- Segment of resected small bowel measured 4.5 x 3.5 cm with submucosal hemorrhage. Resected margins were viable.
- Patient was discharged from the hospital 5 days after surgery.

References:

“ACR.org Home.” *American College of Radiology*, Suspected Small-Bowel Obstruction. ,
<https://acsearch.acr.org/docs/69476/Narrative/>

ASA Physical Status Classification System. American Society of Anesthesiologists October 2014
<https://www.asahq.org/standards-and-guidelines/asa-physical-status-classification-system>

Chang L, Chang M, Chang HM, *et al.* Clinical and Radiological Diagnosis of Gallstone Ileus: A Mini Review.
Emerg Radiol 2018; 25: 189-196

Jones, Jeremy. “Rigler Sign | Radiology Reference Article.” *Radiopaedia.org*, radiopaedia.org/articles/rigler-sign-1.

Keaveny MD, Andrew. “Gallstone Ileus.” *UpToDate*, www.uptodate.com/contents/gallstone-ileus

Nuno-Guzman CM, Marin-Contreras ME, Figueroa-Sanchez M, Corona JL. Gallstone Ileus, Clinical Presentation, Diagnostic and Treatment Approach. *World J Gastrointest Surg* 2016; 8(1): 65-76