

AMSER Rad Path Case of the Month:

67-year-old man with Metastatic Renal Cell Carcinoma

Showly Nicholson BA, Harvard Medical School, MS3

Xuefei Hong MD, Brigham and Women's Hospital, Department of Pathology

Ilana S. Warsofsky, MD, Brigham and Women's Hospital, Department of Radiology

Angela A. Giardino MD, Brigham and Women's Hospital, Department of Radiology

Patient Presentation

Clinical History:

- 60-year-old male with increased serum protein and SPEP show IgM spike diagnosed with Waldenstrom's Macroglobulinemia (WM). Staging CT for WM revealed a large mass in the left kidney which was biopsy proven clear cell renal cell carcinoma (ccRCC).
- Patient underwent left nephrectomy and completed 6 cycles of Bendamustine/Rituximab for WM.

Physical exam:

- Unremarkable

Pertinent labs:

- Non-contributory

ACR Appropriateness Criteria Post Treatment Follow Up and Active Surveillance of Clinically Localized RCC

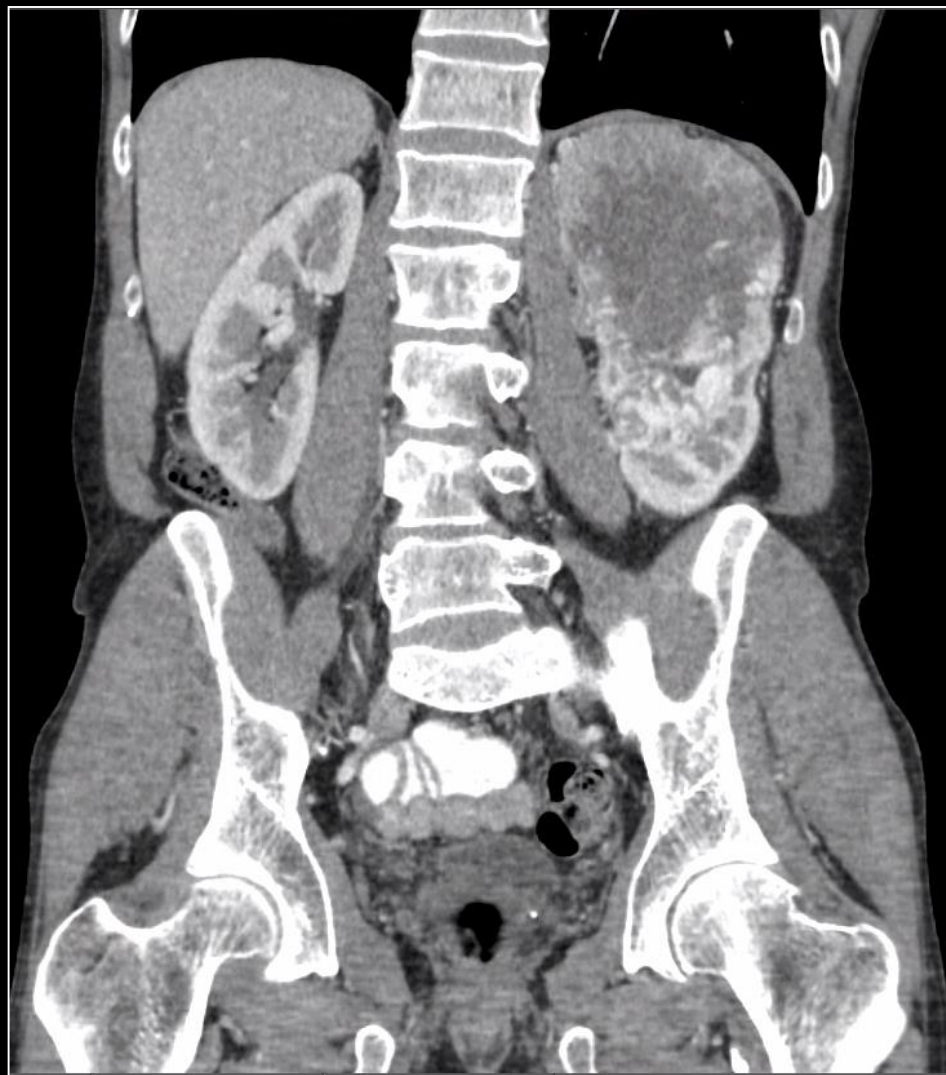Variant 1: Follow-up for clinically localized renal cell cancer; post radical or partial nephrectomy.

Procedure	Appropriateness Category	Relative Radiation Level
CT abdomen with IV contrast	Usually Appropriate	⊕⊕⊕
MRI abdomen without and with IV contrast	Usually Appropriate	○
CT abdomen without and with IV contrast	Usually Appropriate	⊕⊕⊕
CT abdomen and pelvis with IV contrast	May Be Appropriate	⊕⊕⊕
CT abdomen and pelvis without and with IV contrast	May Be Appropriate	⊕⊕⊕⊕
CT chest with IV contrast	May Be Appropriate	⊕⊕⊕
MRI abdomen without IV contrast	May Be Appropriate	○
Radiography chest	May Be Appropriate	⊕
US abdomen with IV contrast	May Be Appropriate	○
CT abdomen without IV contrast	May Be Appropriate	⊕⊕⊕
CT chest without IV contrast	May Be Appropriate	⊕⊕⊕



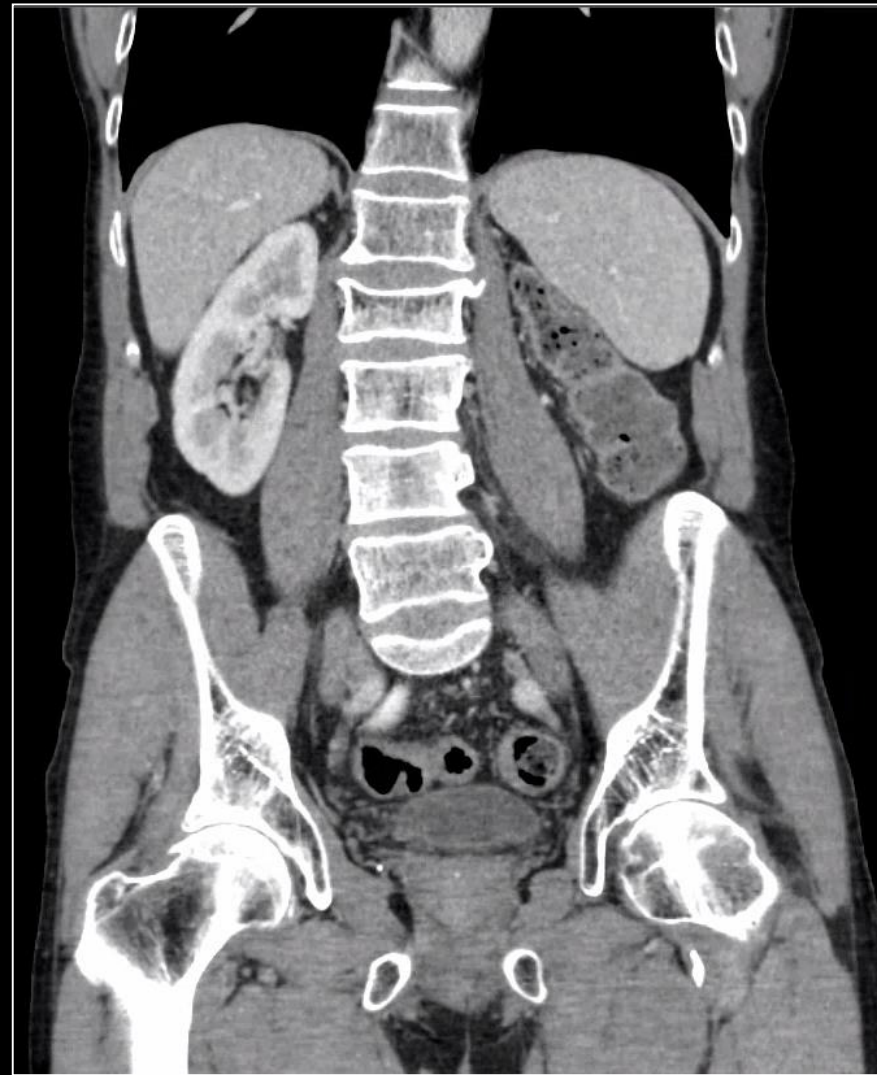Imaging (Unlabeled)

Baseline



Contrast enhanced coronal image.

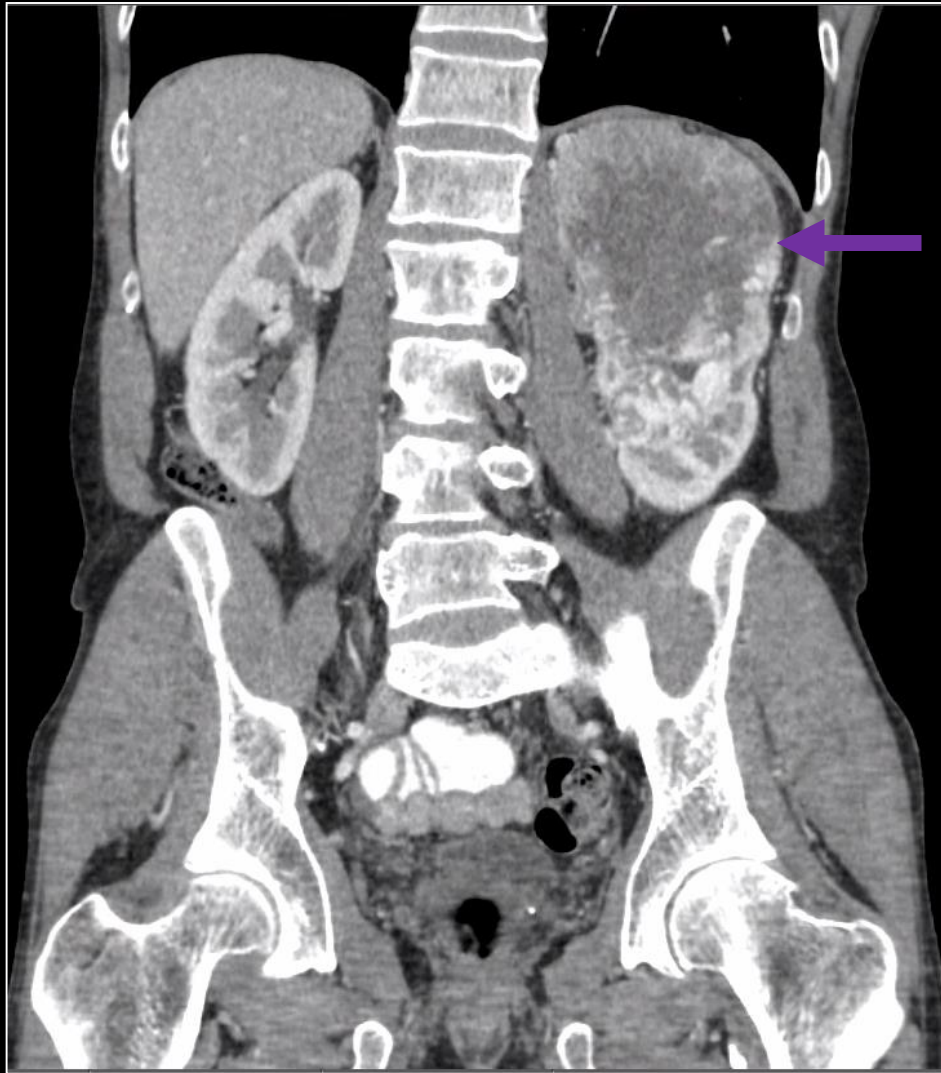
Post Left Nephrectomy



Contrast enhanced coronal image.

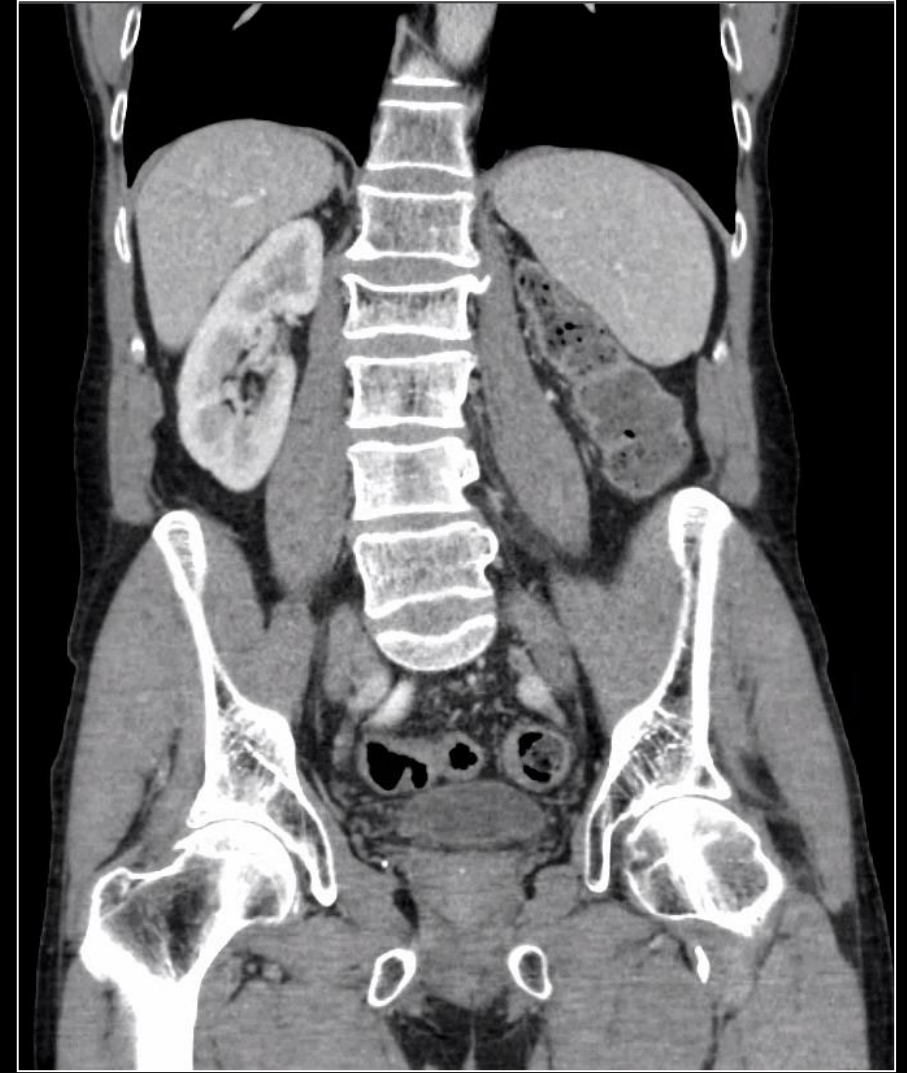
Imaging (Labeled)

Baseline



Contrast enhanced coronal image demonstrates heterogeneously enhancing left renal mass consistent with ccRCC (purple arrow).

Post Left Nephrectomy



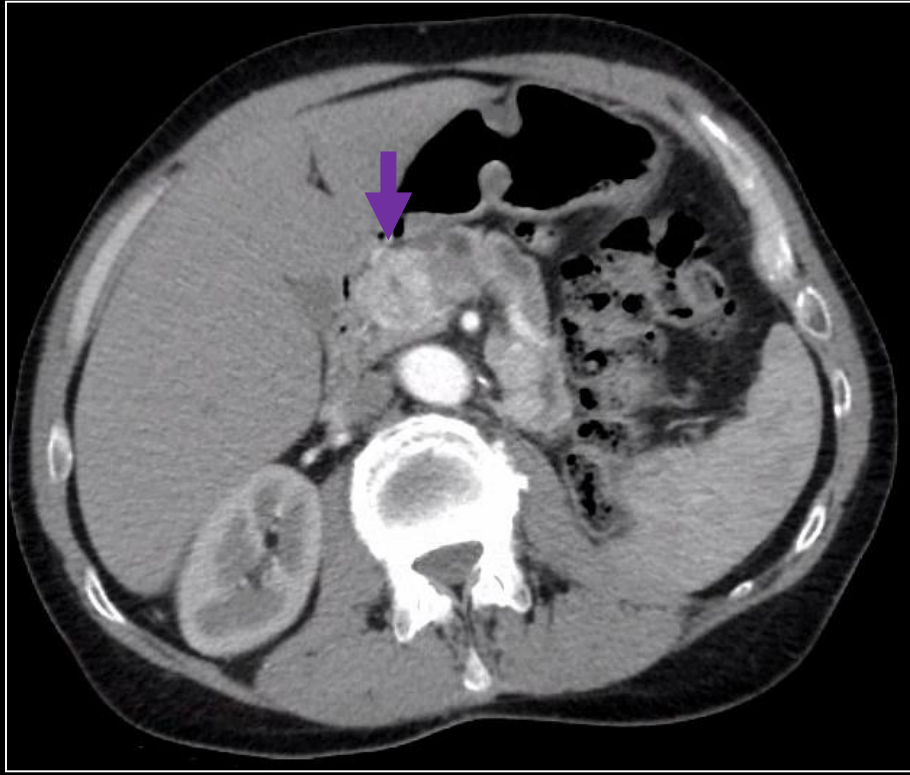
Contrast enhanced coronal image demonstrates no recurrence in the nephrectomy bed.

Patient Presentation

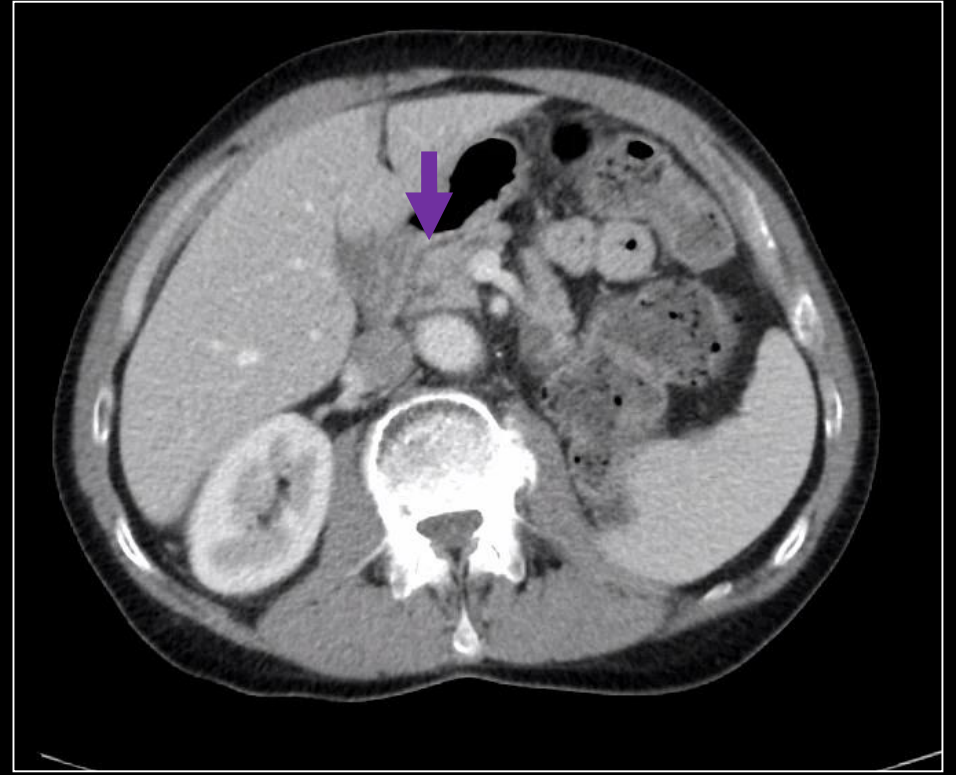
Clinical History:

- Approximately 1 year later, the patient underwent restaging scans which demonstrated pancreatic, peritoneal and mesenteric lesions concerning for metastases. EUS guided FNA of pancreatic head confirmed metastatic ccRCC. Patient began first line treatment with Cabozantinib.
- Restaging scans 3 months later demonstrated decrease in size of metastatic lesions consistent with response in the pancreatic lesion.

Imaging (Labeled)



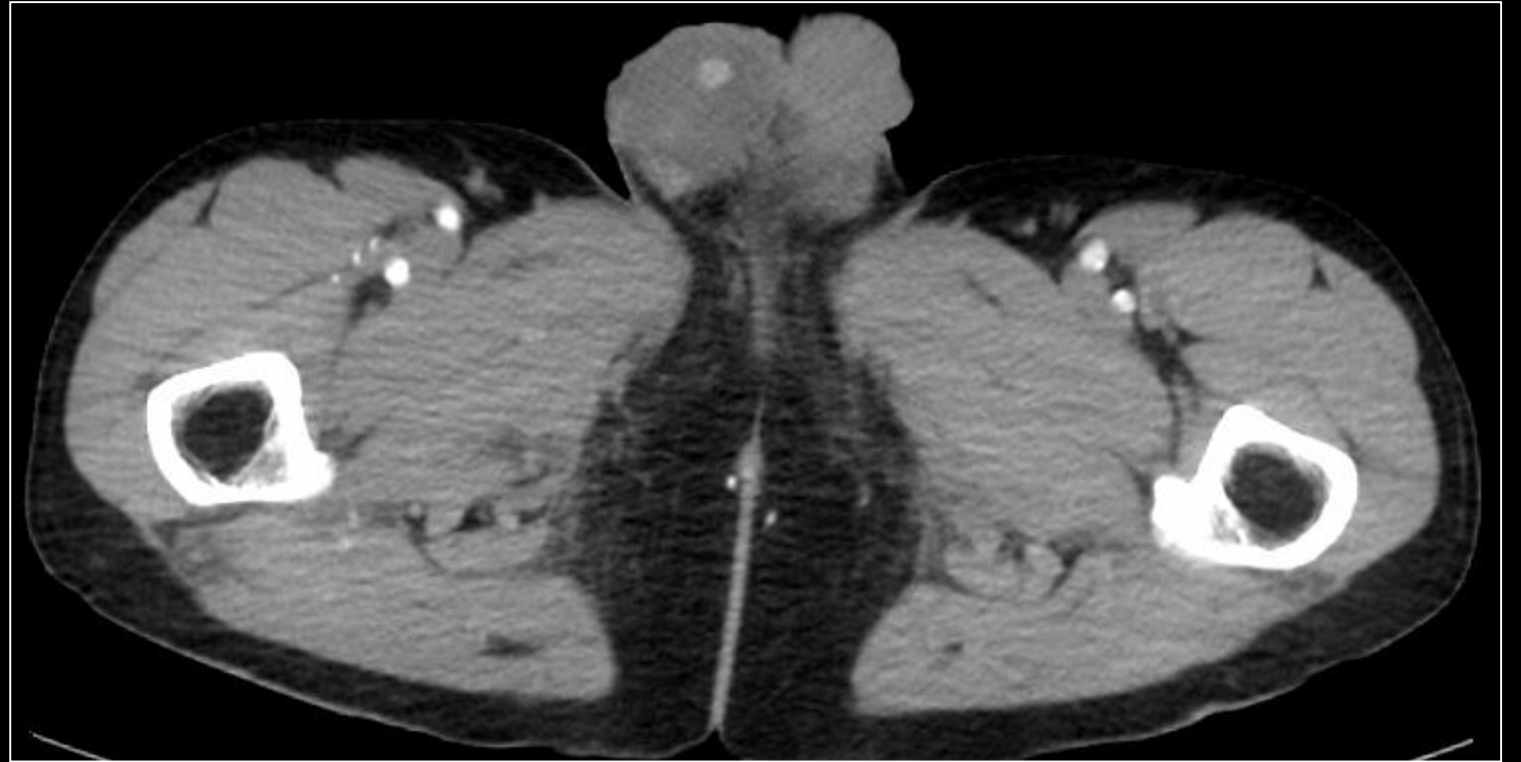
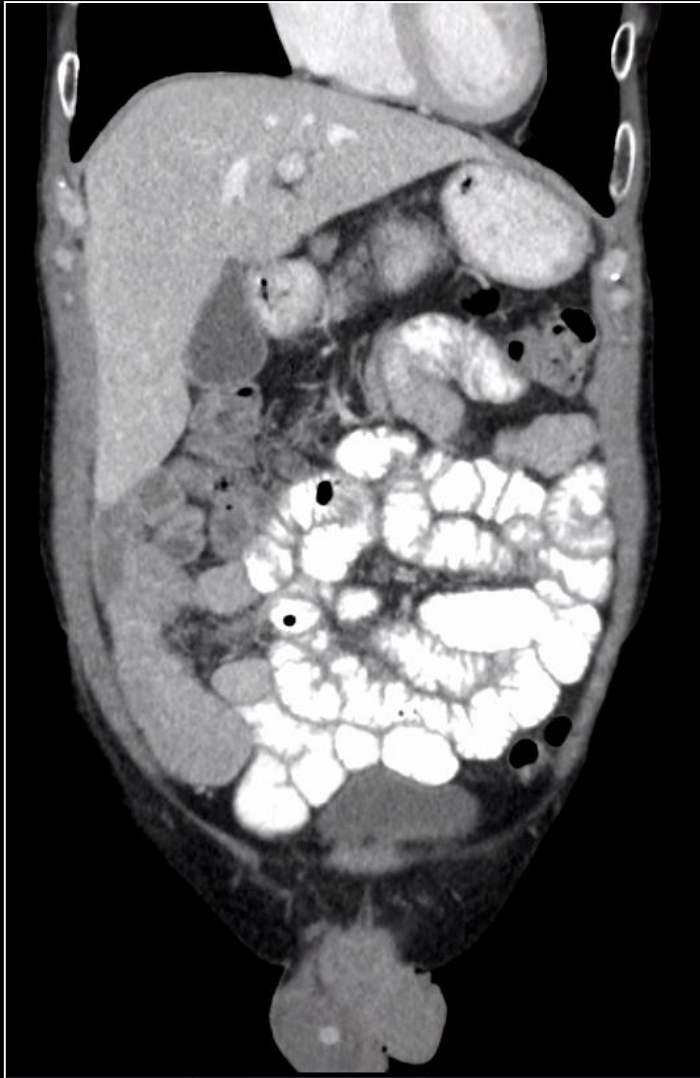Restaging scan 1 year later: Axial contrast enhanced CT shows a heterogeneously enhancing lesion in the pancreatic head which was a biopsy proven ccRCC metastasis (purple arrow). Patient started on Cabozantinib – a therapy that targets and binds to the tyrosine kinase receptors and inhibits the activity of multiple tyrosine kinases, including VEGF, AXL, and MET on the surface of the cell. By binding to these receptors, Cabozantinib blocks important pathways that promote cell division.



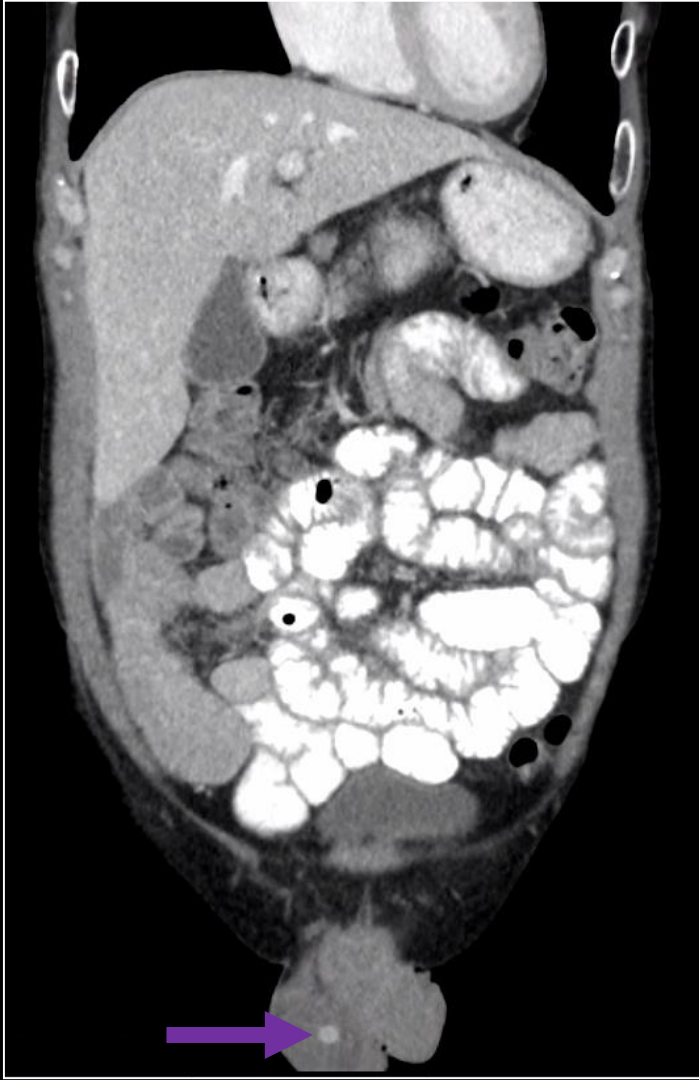Restaging scan 4 months later: Axial contrast enhanced CT shows a complete response. No residual lesion in the pancreatic head.

Imaging (Unlabeled)

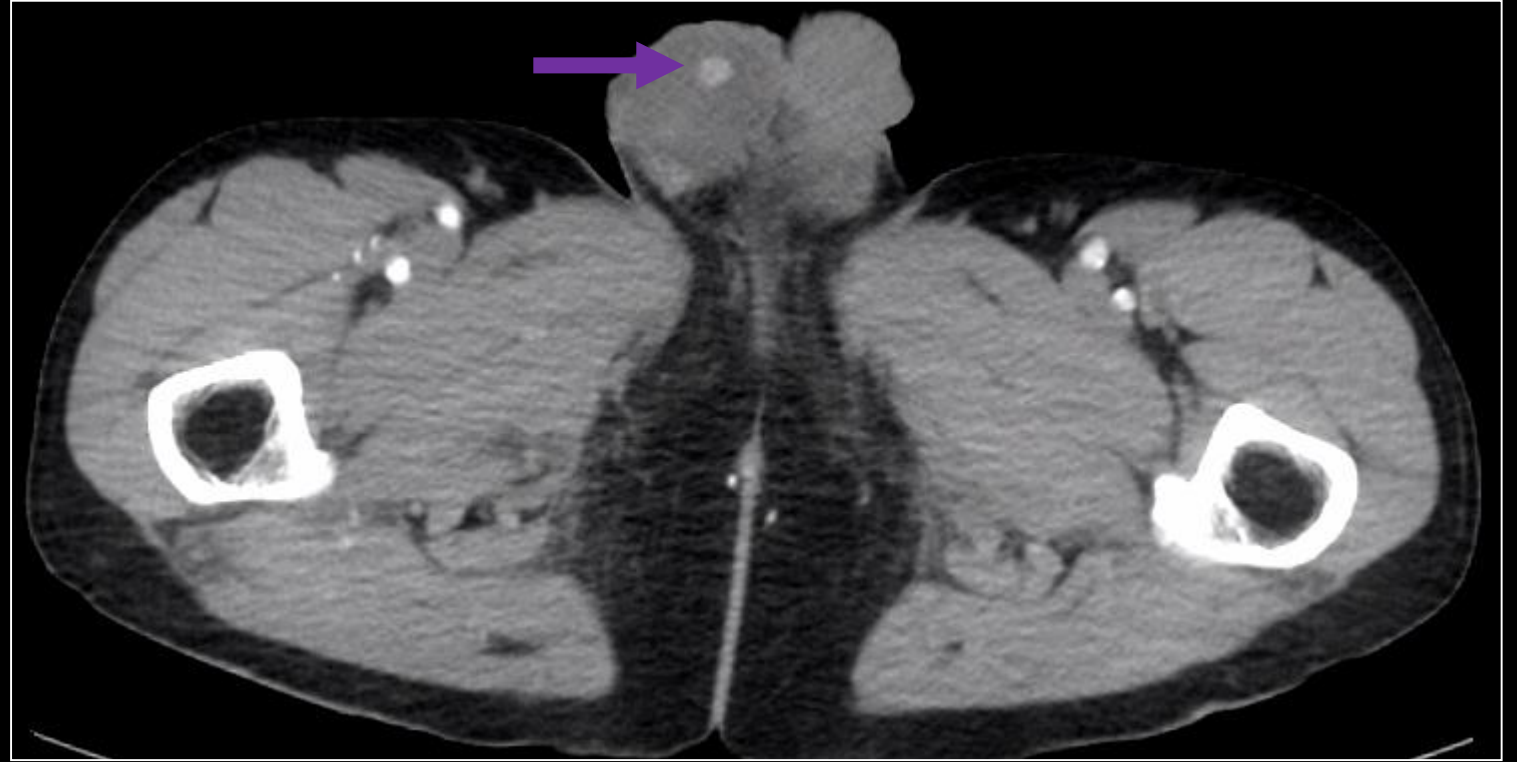Patient has undergone Q3 month restaging scans for approximately 2 years after initiation of Cabozantinib therapy. Below are selected images of a new finding.



Imaging (Labeled)



Contrast enhanced coronal CT image shows a 9mm hyperattenuating lesion in the right testicle (purple arrow).



Axial enhanced coronal CT image shows a 9mm hyperattenuating lesion in the right testicle (purple arrow).

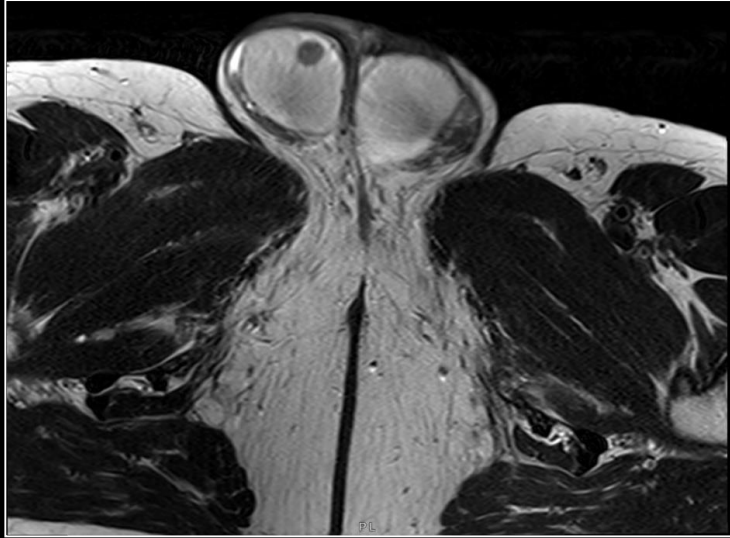
DDX of a Solitary Testicular Mass Based on Imaging:

- Primary malignancy:
 - Seminoma
 - Non-Seminomatous tumors
 - Mixed Tumors
- Metastasis

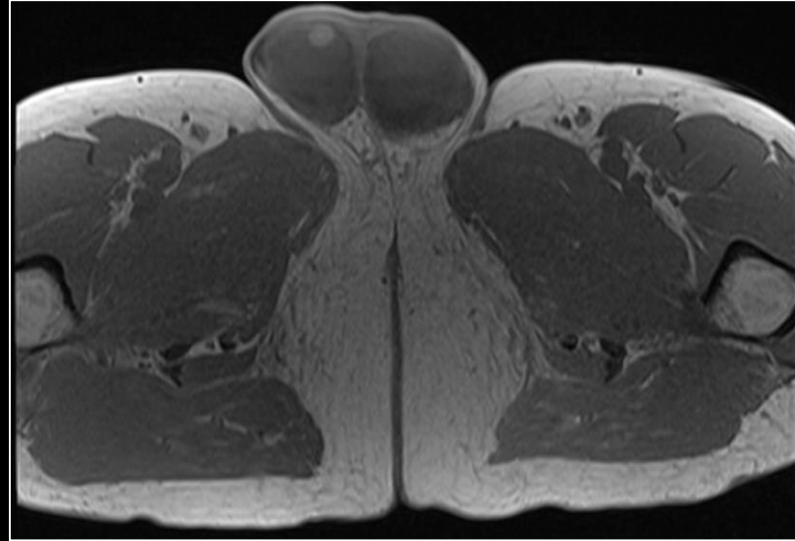
- Other:
 - Lymphoma
 - Granuloma
 - Epidermoid cyst
 - Hematoma
 - Abscess

- No lesion was identified on subsequent testicular ultrasound.
- As such, patient underwent a scrotal MRI with and without contrast.

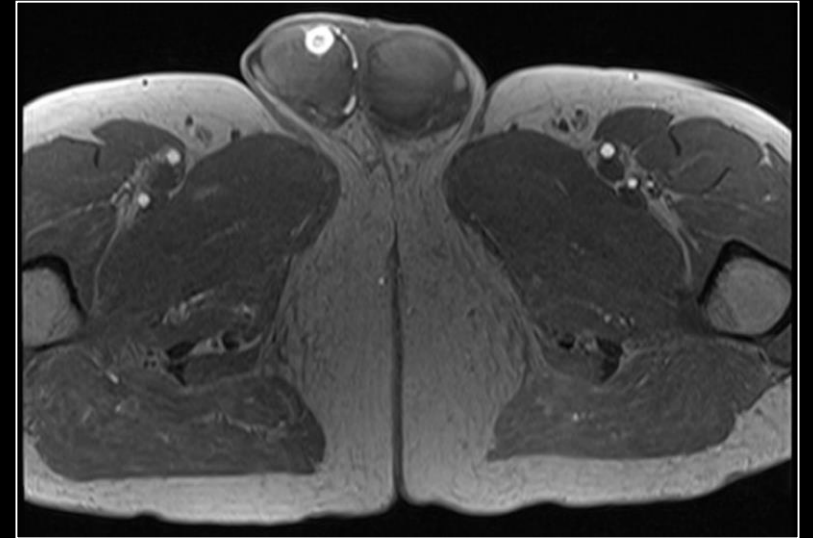
MRI Scrotum (Unlabeled)



Axial T2

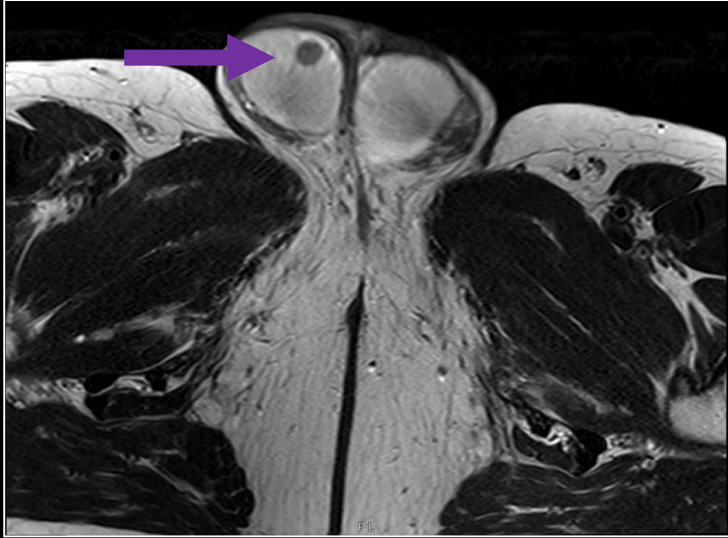


Axial T1 pre-contrast

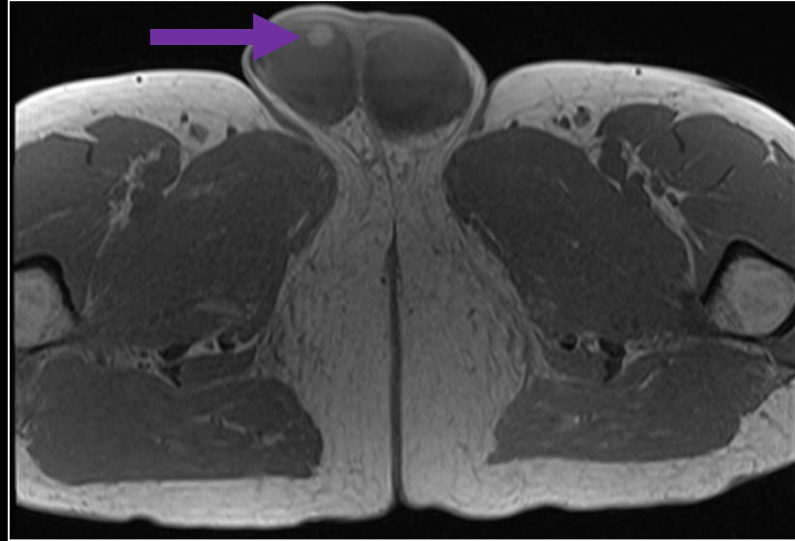


Axial T1 post-contrast

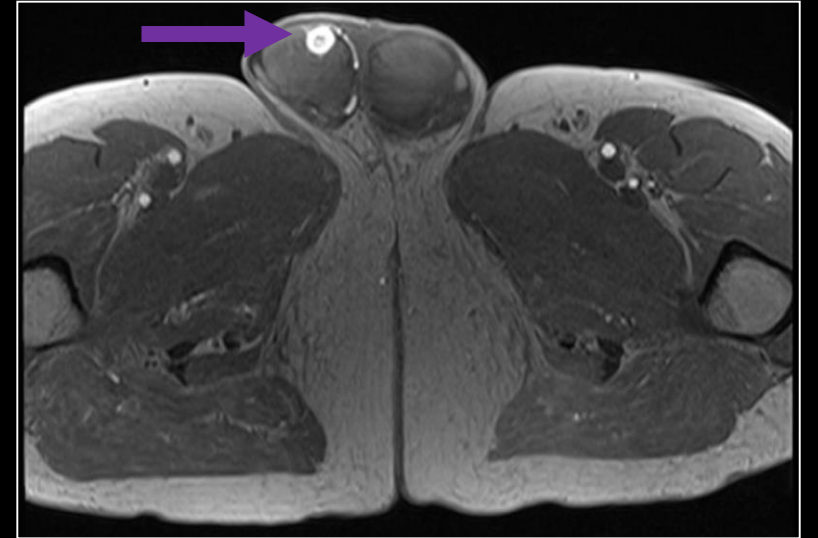
MRI Scrotum (Labeled)



Axial T2



Axial T1 pre-contrast

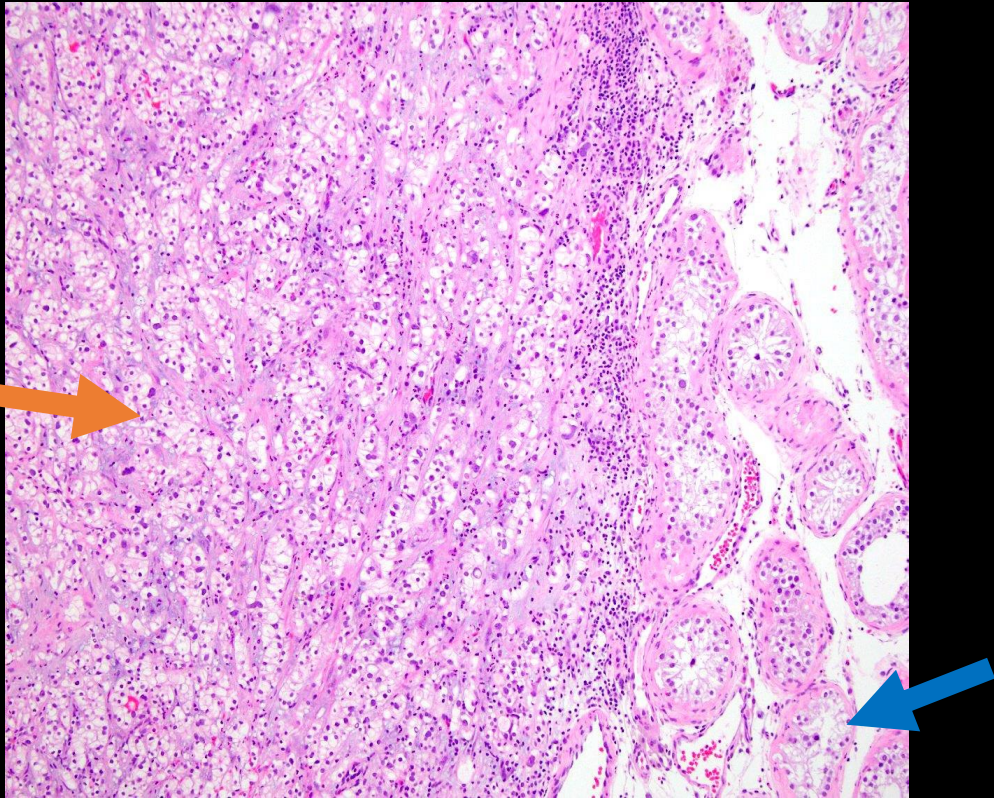


Axial T1 post-contrast

There is a 1 cm T2 hypointense, T1 iso to hypointense enhancing nodule in the right testicle. Because the lesion was indeterminate on imaging and given the patient's clinical history, the patient underwent right orchiectomy.

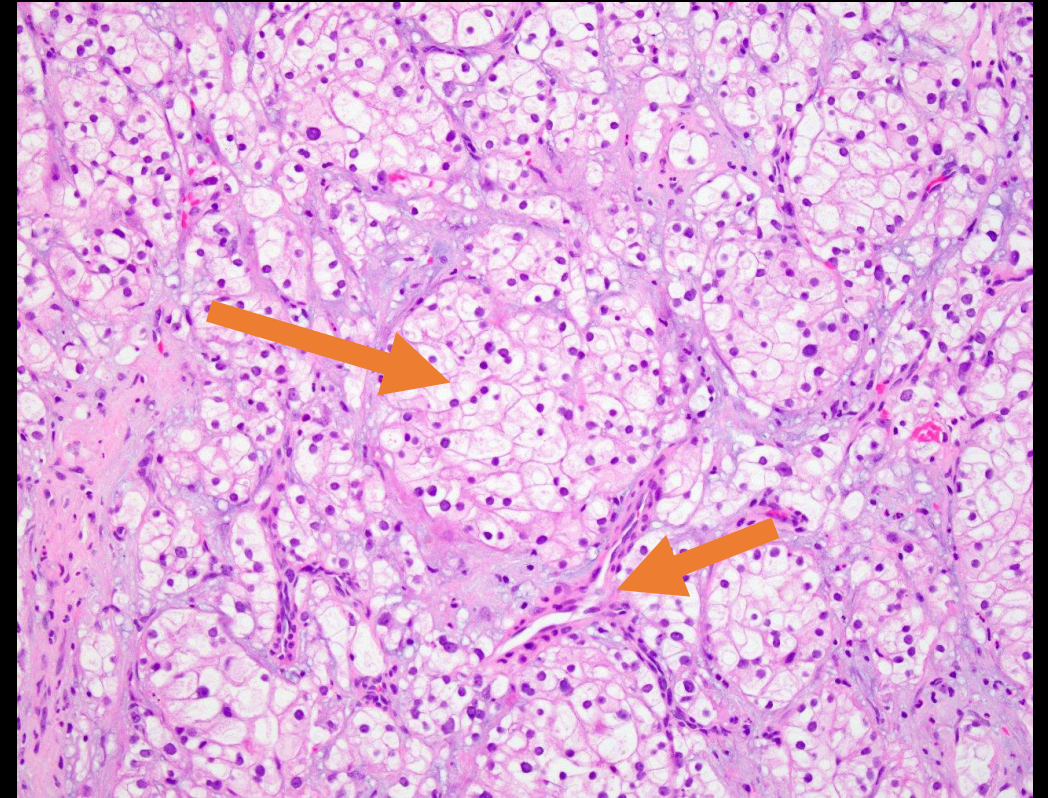
Histopathology

Seminiferous tubules on the left replaced by tumor cells with clear cytoplasm and nested growth pattern (orange arrow). Normal seminiferous tubules on the right side of image (blue arrow).



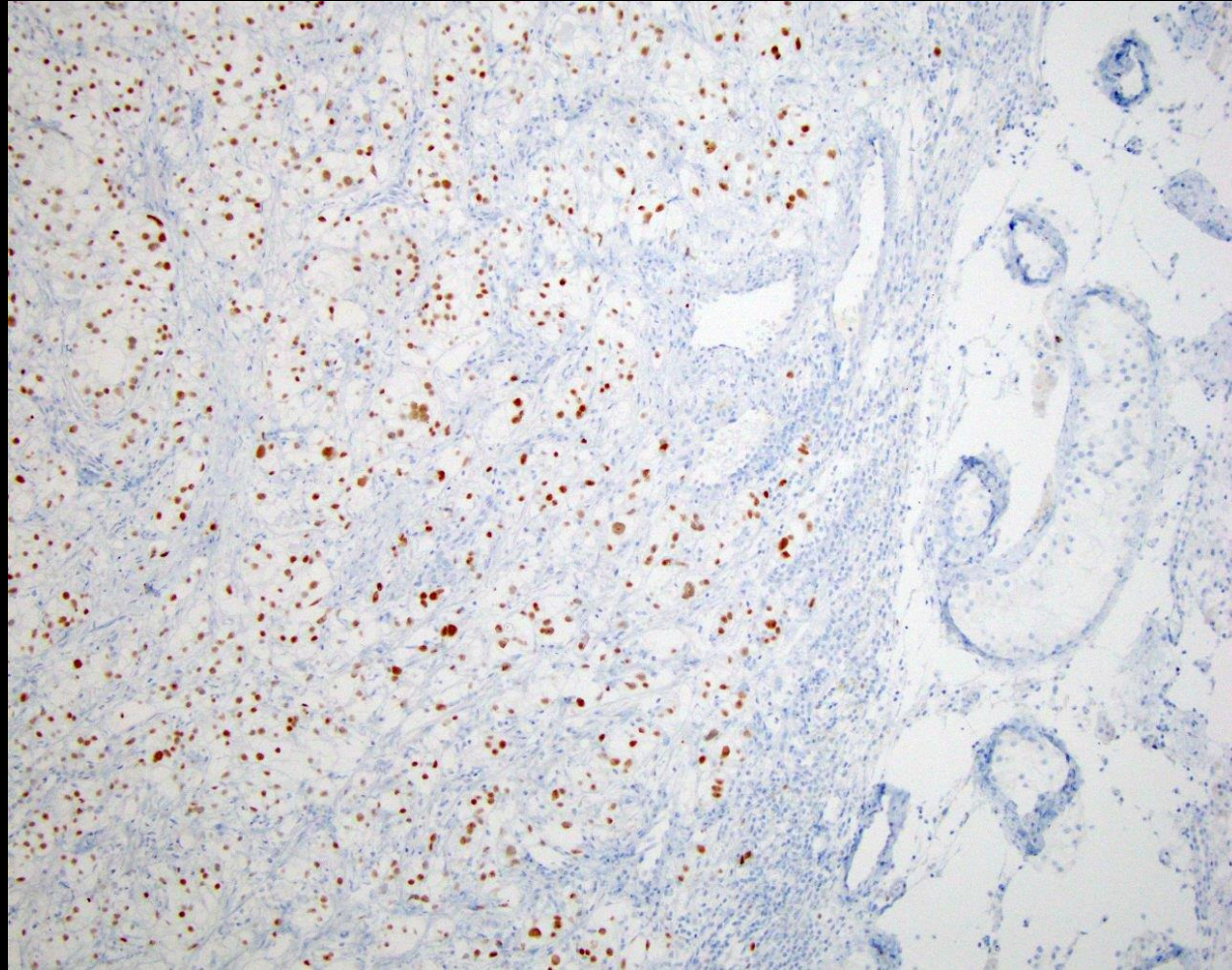
10x magnification on H&E stain

Nests of clear cells surrounded by intricately branching vasculature (orange arrows).



20x magnification on H&E stain

Immunohistochemistry



Immunohistochemical stain positive for PAX8, a transcription factor for renal organogenesis and a marker for primary and metastatic renal cell carcinoma.

Final Diagnosis

Metastatic Clear Cell Renal Cell Carcinoma to the Right Testis

Discussion: Clear Cell Renal Cell Carcinoma

- RCC is the most common renal malignancy.
- Of the major subtypes, clear cell RCC (ccRCC) is the most common accounting for 75% of cases.
- ccRCC is characterized by loss of the short arm of chromosome 3 (3p) which harbors the Von Hippel Lindau (VHL) tumor suppressor gene.
- Dependence of ccRCC on the VEGF mediated pathway of angiogenesis provides a target for novel anti-cancer treatments such as anti-VEGF agents including bevacizumab, cabozantinib, sunitinib, and pazopanib.

Discussion: Clear Cell Renal Cell Carcinoma

- Most common sites of metastases from ccRCC:
 - Lungs
 - Bone
 - Liver
 - Head and neck
 - Local lymph nodes
 - Pancreas and Renal metastases (**more common with ccRCC)

Discussion: Clear Cell Renal Cell Carcinoma

- Testicular metastases are exceedingly rare. Based on literature review, there have been less than 40 cases reported, with the first case report in 1946^[6].
 - RCC metastasis to the testis is most commonly ipsilateral and affects the left side likely due to retrograde migration of tumor cells through the left testicular vein.
 - Contralateral metastases are even more rare and believed to occur via hematogenous spread through Batson's plexus.
- 2 prominent theories regarding why testicular spread is rare^[5]:
 - Low basal temperature of the testes is an unfavorable environment for metastatic proliferation
 - Sertoli cells forms the blood-testis barrier which plays an indirect role in preventing testicular metastases

References:

1. Patel U, Sokhi H. Imaging in the follow-up of renal cell carcinoma. *AJR Am J Roentgenol*. 2012 Jun;198(6):1266-76.
2. Coursey Moreno C, Small WC, Camacho JC, Master V, Kokabi N, Lewis M, Hartman M, Mittal PK. Testicular tumors: what radiologists need to know--differential diagnosis, staging, and management. *Radiographics*. 2015 Mar-Apr;35(2):400-15.
3. Tsili AC, Argyropoulou MI, Giannakis D, Sofikitis N, Tsampoulas K. MRI in the characterization and local staging of testicular neoplasms. *AJR Am J Roentgenol*. 2010 Mar;194(3):682-9.
4. Wang G, Zhou C, Villamil CF, So A, Yuan R, English JC, Jones EC. Metastatic Renal Cell Carcinoma to the Testis: A Clinicopathologic Analysis of Five Cases. *Case Rep Pathol*. 2020 Mar 2;2020:9394680.
5. Kolukcu E, Kilic S, Parlaktas BS, Deresoy FA, Atilgan D, Gumusay O, Uluocak N. Contralateral Testicular Metastasis of Renal Cell Carcinoma: A Case Report. *Eurasian J Med*. 2019 Oct;51(3):310-312.
6. Bandler CG, Roen PR. Solitary testicular metastasis simulating primary tumor and antedating clinical hypernephroma of the kidney; report of a case. *J Urol*. 1946 Jun;55:663-9.
7. Shinagare AB, Krajewski KM, Braschi-Amirfarzan M, Ramaiya NH. Advanced Renal Cell Carcinoma: Role of the Radiologist in the Era of Precision Medicine. *Radiology*. 2017 Aug;284(2):333-351.